

# An Unusual Case of Osteoarthritis?

Mariana Teixeira<sup>1</sup>, Joana Ricardo Pires<sup>1</sup>, Filipa Ferreira<sup>1</sup>, Tiago Rabadão<sup>1</sup>, Marcelo Aveiro<sup>1</sup>, Nuno Neves<sup>1</sup>, and Clarinda Neves<sup>1</sup>

<sup>1</sup>Centro Hospitalar do Baixo Vouga EPE

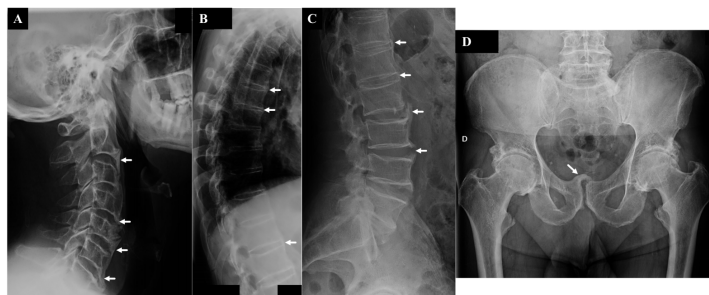
June 24, 2021

## Abstract

Forestier disease is a condition characterized by calcification and ossification of ligaments and entheses. It's prevalence is expected to rise as air is related to older age and metabolic syndrome. The clinical relevance is beyond unstable spinal fractures to involvement of the cardiovascular, respiratory and gastrointestinal systems.

## Hosted file

artigo DISH\_2.1.pdf available at <https://authorea.com/users/421547/articles/527536-an-unusual-case-of-osteoarthritis>



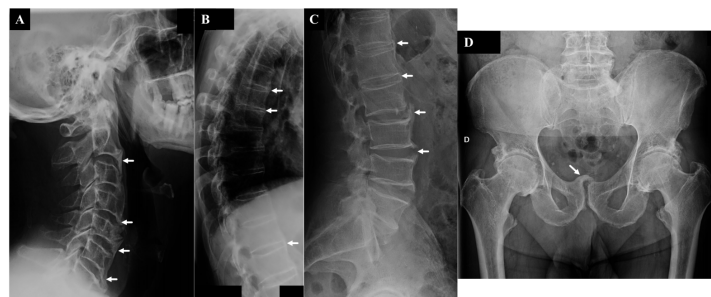


Figure A: Cervical spine radiography revealing thickening and ossification of anterior longitudinal ligament (arrows) .

Figure B: Thoracic spine radiography revealing ossification of anterior longitudinal ligament (arrows).

Figure C: Lumbar spine radiography revealing large non marginal osteophytes (arrows).

Figure D: Pubic symphysis enthesopathy (arrow).