

Morphea in two patients after being infected to and being vaccinated against SARS-CoV-2 infection

Zeinab Aryanian¹, Kamran Balighi¹, Parvaneh Hatami¹, Nasim Tootoonchi², Azadeh Goodarzi³, and Zeinab Mohseni Afshar⁴

¹TUMS

²Tehran University of Medical Sciences

³Iran University of Medical Sciences

⁴Kermanshah University of Medical Sciences

March 14, 2022

Abstract

Although the presence of morphea following COVID-19 has been rarely reported, development of its generalized form following COVID-19 vaccination has not been reported yet. Here, we reported the first case of generalized morphea following COVID-19 vaccination and another similar case following SARS-Cov-2 infection. Other etiologic factors were also dealt with

Morphea in two patients after being infected to and being vaccinated against SARS-CoV-2 infection

Zeinab Aryanian^{1,2}, Kamran Balighi^{1,3}, Parvaneh Hatami^{1*}, Nasim Mazlumi Tootoonchi ^{1,3} , Azadeh Goodarzi ^{4,5}and Zeinab Mohseni Afshar ^{6*}

1. Autoimmune Bullous Diseases Research Center, Tehran University of Medical Sciences, Tehran, Iran.
2. Department of Dermatology, Babol University of Medical Sciences, Babol, Iran
3. Department of Dermatology, Razi Hospital, Tehran University of Medical Sciences, Tehran, Iran
4. Department of Dermatology, Rasoul-e- Akram Hospital, Iran University of Medical Sciences, Tehran, Iran
5. Skin and Stem Cell Research Center, Tehran, Iran
6. Clinical Research Development Center, Imam Reza Hospital, Kermanshah University of Medical Sciences, Kermanshah, Iran

*Correspondence to

*Zeinab Mohseni Afshar, Clinical Research Development Center, Imam Reza Hospital, Kermanshah University of Medical Sciences, Kermanshah, Iran

Email: zeinabafshar710@gmail.com

Tel: 09111156511

Post Code: 9137913316

*Parvaneh Hatami, Autoimmune Bullous Diseases Research Center, Razi hospital ,Tehran University of Medical Sciences, Tehran, Iran

Email: p_hatami2001@yahoo.com

Tel: 09124848444

Post Code: 1199663911

Abstract:

Although the presence of morphea following COVID-19 has been rarely reported, development of its generalized form following COVID-19 vaccination has not been reported yet. Here, we reported the first case of generalized morphea following COVID-19 vaccination and another similar case following SARS-Cov-2 infection. Other etiologic factors were also dealt with.

Key Words: Morphea; COVID; COVID vaccination; AstraZeneca; SARS-Cov-2

Key Clinical Message:

COVID-19, and recently the associated vaccines, have led to any dermatologic condition. Here, we reported the first case of generalized morphea following COVID-19 vaccination and another similar case following SARS-Cov-2 infection.

Introduction

Since the emergence of the SARS-CoV-2 pandemic, various dermatological manifestations have been demonstrated both following the de novo infection and the associated vaccination(1-4). These cutaneous adverse events have been either a new-onset dermatologic disorder, or exacerbation of the pre-existing one(5, 6). The new-onset or flare-up of psoriasis, lichen planus, eczematous dermatitis, and many other dermatoses have been reported following COVID-19(7-11). On the other hand, dermatologic complications have also been abundantly observed after being vaccinated against SARS-CoV-2(12, 13). However, SARS-CoV-2 related morphea has been reported only in few articles. Moreover, to our knowledge, morphea has not yet been demonstrated after COVID-19 vaccination and our case seems to be the first one.

Here, we present two cases of new-onset morphea arising after SARS-CoV-2 infection and vaccination.

Case presentation

Case 1

A 29-year old woman presented to the dermatologic clinic with multiple sclerotic skin eruptions all over her body. She mentioned a history of SARS-CoV-2 infection 4 months earlier. A few days after being infected, she had developed maculopapular lesions beginning from the upper extremities progressing to the trunk and lower extremities. The eruptions gradually turned to sclerotic lesions (figure1). She did not have any comorbidities and her medication history was not significant except for a course of interferon beta-1a during her SARS-CoV-2 infection. Complete blood count, chemistry panel, liver, renal and thyroid function tests and coagulation parameters were in normal range. Complement component C3 and C4, erythrocyte sedimentation rate (ESR), C-reactive protein (CRP), and ferritin levels were within normal limits. Serologic tests for ACE, ANA, RF, Anti-dsDNA, AntiRo, Anti La, Anti Sm, Anti Jo1, AntiScl70, Anti RNP, Anti-centromere, Anti-CCP, and FANA antibodies were negative. Moreover, assessment results for tumor markers, hepatitis B virus (HBV) and hepatitis C virus (HCV) were also negative. Abdominopelvic ultrasound did not reveal any abnormality. We took skin biopsy of the eruptions, which demonstrated the epidermis overlying by basket weave cornified layer with basilar pigmentation and also the dermis infiltrated by perivascular and slight interstitial lympho-histiocytes and scattered plasma cells, with sclerotic change and diminished adnexa, all suggestive for morphea. We treated the patient with topical corticosteroids, but no response was observed. Therefore, we recommended the patient to undergo phototherapy. At the current time, she has passed her second phototherapy session with no considerable response. Yet, we are expecting to observe improvement with more prolonged duration of therapy.

Case 2

A 70-year-old woman attended our dermatology clinic with diffuse skin eruptions of one month duration. She complained of a progressive maculopapular rash beginning from the arms, and extending to all the body surface, with gradual stiffness of the lesions. She acknowledged that the condition started 2 days after getting the first dose of AstraZeneca SARS-CoV-2 vaccine. Physical examination revealed multiple sclerotic skin eruptions all over the body including intertriginous areas (figure 2). Deep skin biopsy revealed sclerodermoid changes. Her polymerase chain reaction (PCR) test for SARS-CoV-2 was reported negative. Other laboratory tests including complete rheumatology panel were normal. Tumor markers and other assessments for malignancies also did not reveal an underlying cancer. Our patient refused to undergo phototherapy, so we started her on methotrexate and topical corticosteroids and are waiting to see the response.

Discussion

The present report investigated two cases of generalized morphea that developed and rapidly progressed within a few days after SARS-CoV-2 infection and vaccination, both in individuals with no history of rheumatologic or autoimmune disorders.

Localized scleroderma, also known as morphea, is a dermatologic disorder which leads to loss of elasticity and hardening of the skin. This dermatosis is classified as plaque morphea, generalized morphea, linear scleroderma and deep morphea(14). The generalized form of morphea is defined as skin induration and sclerosis in the form of plaques in at least four anatomic sites, including head-neck, each extremity, anterior trunk, and posterior trunk(14). This condition is quite serious and rapidly progressive, and has an unfavorable outcome(15). Considering the characteristics and pattern of eruptions onset, our cases was considered as cases of generalized morphea.

The pathophysiologic mechanism for morphea is still unknown, however, it seems to be the result of immune activation leading to connective tissue dysregulation(16).

Morphea might be related to some environmental factors such as trauma, radiation, medications, infections and vaccines(17). *Borrelia burgdorferi* has been the most common infective pathogen reported to be associated with morphea(18). Other infections with probable association include hepatitis B virus (HBV), hepatitis C virus (HCV), cytomegalovirus (CMV), toxoplasma, helicobacter pylori, and human endogenous retroviruses (HERV)(19-25). Recently, we have confronted with cases of morphea following SARS-CoV-2 infection(8, 9). The underlying mechanism might be the virus-induced inflammation which gives rise to immune system activation or cross reaction of the virus and the host skin antigens(26). Skin is among the important organs that is involved in the course of any viral infection, including SARS-CoV-2, as we have demonstrated a wide variety of dermatologic complications in the settings of COVID-19, either as the presenting manifestation or occurring in the course of the infection(1, 26).

On the other hand, we can name Diphtheria-Tetanus-Pertussis (DTP), hepatitis B, BCG, and pneumococcal vaccines among the ones reported to be associated with morphea(27-32). However, most of the aforementioned conditions occurred locally and in the vaccine injection sites, rather than appearing in generalized types(28, 30). Up to the present time, no case of morphea has been reported following SARS-CoV-2 vaccination. Nevertheless, it is expected to detect more cases due to the hyperimmune responses following any vaccines, including those for COVID-19. Due to the temporal relationship between the morphea onset and vaccine injection, and considering the negative laboratory results for infections, rheumatologic and malignant disorders, we attributed the condition of our second case to SARS-CoV-2 vaccination.

It is important to note that morphea can also appear as a component of a systemic autoimmune disorder such as systemic scleroderma, lupus erythematosus, thyroiditis, eosinophilic fasciitis, and biliary cirrhosis(33). Most cases of generalized morphea have been reported in association with positive serologic tests results for autoantibodies, particularly ANA(34). We evaluated both of the patients for autoimmune rheumatologic diseases, autoimmune thyroiditis, HCV and HBV, and IgE levels, none of which turned positive. Moreover, some malignancies have been first presented with cutaneous manifestations, such as morphea(35-37). Accordingly, we performed a thorough work-up to detect any malignancies being presented with morphea as a paraneoplastic sign. Therefore, we attributed the condition to infection and vaccination.

Another important issue is the difficulty in differentiating between generalized morphea and systemic sclerosis clinically. However, the absence of Raynaud phenomenon and sclerodactyly and also the negative results for ANA, Anti-centromere, and AntiScl70 justified our diagnosis, which was confirmed with histopathology(38).

We should take into account that some of the therapeutics utilized for managing COVID-19 can lead to florid cutaneous reactions(39). For example, Stevens-Johnson-like syndrome, acute generalized exanthematous pustulosis and urticarial eruptions have been reported following hydroxychloroquine, acneiform eruptions and localized scleroderma following ribavirin, and psoriasis, alopecia, cutaneous vasculitis, and lichenoid drug reactions have been observed after receiving interferons(40, 41). Our first patient had received interferon beta-1a for her SARS-CoV-2 infection. There have been rare reports of localized morphea at the site of interferon injection(42); however, no case of generalized morphea has been reported in patients who had received this medication. Nonetheless, we should consider the medications, along with the de novo infection as the precipitating factors of the cutaneous reaction in our first patient.

Topical tacrolimus, methotrexate, systemic steroids, D-penicillamine, mycophenolate mofetil, cyclosporine, imiquimod, and calcipotriol have all been applied in managing morphea(43); however, artificial ultraviolet (UV) radiation or phototherapy has been the most effective and the mainstay of treatment(44).

Conclusion

COVID-19, and recently the associated vaccines, have led to any dermatologic condition, including insignificant and critical ones. Therefore, we should take into account these entities in any patient presenting with new-onset or exacerbating cutaneous reaction.

Ethics approval:

Ethical approval from the Medical Ethics Committee of Tehran University of Medical Sciences was provided.

Consent for publication:

A written informed consent was obtained from the patients for publication of this case report and any accompanying images. A copy of the written consent is available for review by the Editor-in-Chief of this journal.

Competing interests

The authors declare that they have no competing interests.

Availability of supporting data: The data that support the findings of this study are available from the corresponding author, upon reasonable request.

Funding:

None

Author contribution:

All the authors listed above have equally participated in preparing the manuscript.

Acknowledgments:

The study was performed at the Autoimmune Bullous Diseases Research Center, Razi Hospital, Tehran, Iran.

References:

1. Mohseni Afshar Z, Babazadeh A, Hasanpour A, Barary M, Sayad B, Janbakhsh A, et al. Dermatological manifestations associated with COVID-19: A comprehensive review of the current knowledge. *Journal of medical virology*. 2021;93(10):5756-67.

2. Hatami P, Nicknam Asl H, Aryanian Z. Cutaneous Manifestations of COVID-19 in Children: Practical Points for Clinicians. *J Skin Stem Cell*.8(4):e122260. doi: 10.5812/jssc.122260.
3. Hatami P, Aryanian Z., Nicknam Asl H, Goodarzi A. Mucocutaneous adverse effects following COVID-19 vaccination: A comprehensive review of the literature with a presentation of some cases from Iran. *Iranian Journal of Dermatology*.2021 Dec. Doi: 10.22034/IJD.2021.311094.1451
4. Mohaghegh F, Hatami P, Aryanian Z. A case of atypical disseminated herpes zoster in a patient with COVID-19; a diagnostic challenge in COVID era. *J Clinical Case Reports*. 2022. Doi: 10.1002/ccr3.5342
5. Miladi R, Janbakhsh A, Babazadeh A, Aryanian Z, Ebrahimpour S, Barary M, et al. Pustular psoriasis flare-up in a patient with COVID-19. *Journal of Cosmetic Dermatology*. 2021;20(11):3364-8.
6. Babazadeh A, Miladi R, Barary M, Shirvani M, Ebrahimpour S, Afshar ZM. COVID-19 vaccine-related new-onset lichen planus. *Authorea Preprints*. 2021.
7. Pigliacelli F, Pacifico A, Mariano M, D'Arino A, Cristaudo A, Iacovelli P. Morphea induced by SARS-CoV-2 infection: A case report. *International journal of dermatology*. 2021.
8. Lotfi Z, Haghighi A, Akbarzadehpasha A, Mozafarpour S, Goodarzi A. Pansclerotic morphea following COVID-19: A case report and review of literature on rheumatologic and non-rheumatologic dermatologic immune-mediated disorders induced by SARS-CoV-2. *Frontiers in medicine*. 2021;8.
9. Hatami P, Balighi K, Nicknam Asl H, Aryanian Z. Serious health threat of mucormycosis during the ongoing COVID-19 pandemic: what dermatologists need to know in this regards.*Int. J. Derm*.2022 Jan
10. Severino P. Morphea (Localized Scleroderma) in a COVID-19 patient: A Case Report. *J Clin Immunol Microbiol*. 2021;2(1):1-4.
11. Hatami P, Balighi K, Nicknam Asl H, Aryanian Z. COVID vaccination in patients under treatment with rituximab: A presentation of two cases from Iran and a review of the current knowledge with a specific focus on pemphigus. *Dermatol Ther*. 2021 Nov 23:e15216. doi: 10.1111/dth.15216. Epub ahead of print. PMID: 34811862.
12. Bogdanov G, Bogdanov I, Kazandjieva J, Tsankov N. Cutaneous adverse effects of the available COVID-19 vaccines. *Clinics in Dermatology*. 2021.
13. Burlando M, Herzum A, Micalizzi C, Cozzani E, Parodi A. Cutaneous reactions to COVID-19 vaccine at the dermatology primary care. *Immunity, inflammation and disease*. 2021.
14. Fett N, Werth VP. Update on morphea: part I. Epidemiology, clinical presentation, and pathogenesis. *Journal of the American Academy of Dermatology*. 2011;64(2):217-28.
15. Coelho-Macias V, Mendes-Bastos P, Assis-Pacheco F, Cardoso J. Imatinib: a novel treatment approach for generalized morphea. *International journal of dermatology*. 2014;53(10):1299-302.
16. Khatri S, Torok KS, Mirizio E, Liu C, Astakhova K. Autoantibodies in morphea: an update. *Frontiers in immunology*. 2019;10:1487.
17. Farhangdoost F. The role of infection in morphea disease. *Reviews in Clinical Medicine*. 2015;2(4):187-9.
18. Şandru F, Popa A, Petca A, Miulescu RG, Constantin MM, Petca RC, et al. Etiologic role of *Borrelia burgdorferi* in morphea: A case report. *Experimental and Therapeutic Medicine*. 2020;20(3):2373-6.
19. Soylu S, Gül Ü, Gönül M, Kilic A, Çakmak SK, Demiriz M. An Uncommon Presentation of the Co-Existence of Morphea and Vitiligo in a Patient with Chronic Hepatitis B Virus Infection. *American journal of clinical dermatology*. 2009;10(5):336-8.
20. Solovăstru L, Amălinei C. Morphea associated with toxoplasmosis. *Revista medico-chirurgicala a Societatii de Medici si Naturalisti din Iasi*. 2003;107(3):646-9.

21. Bashir AH, EL-Hassan LA, Muddathir AK, Mithani A, Sidahmed AB, Elhassan GO, et al. Case Report: Morphea Profunda Associated with Helicobacter pylori Infection in Sudanese Patient. *American Journal of Dermatology and Venereology*. 2015;4(2):13-4.
22. Telakis E, Nikolaou A. Localized scleroderma (morphea) in a patient with chronic hepatitis C. *European journal of gastroenterology & hepatology*. 2009;21(4):396.
23. de Oliveira FL, de Barros Silveira LKC, Rambaldi MLC, Barbosa FC. Localized scleroderma associated with chronic hepatitis C. *Case reports in dermatological medicine*. 2012;2012.
24. Nahidi Y, Tayyebi Meibodi N, Meshkat Z, Salehi M, Farhangdoost F. Evaluation of the association between Morphea and Cytomegalovirus in a cross sectional study. *medical journal of mashhad university of medical sciences*. 2017;60(3):494-502.
25. Kowalczyk MJ, Dańczak-Pazdrowska A, Szramka-Pawlak B, Żaba R, Osmola-Mańkowska A, Silny W. Human endogenous retroviruses and chosen disease parameters in morphea. *Advances in Dermatology and Allergology/Postpy Dermatologii i Alergologii*. 2017;34(1):47.
26. Ehrenfeld M, Tincani A, Andreoli L, Cattalini M, Greenbaum A, Kanduc D, et al. Covid-19 and autoimmunity. *Autoimmunity reviews*. 2020;19(8):102597.
27. Nobari NN, Montazer F, Seirafianpour F, Goodarzi A. Histopathologic changes and cellular events of organs systems in COVID-19. *Journal of Cellular and Molecular Anesthesia*. 2021;6(1):81-8.
28. Viladomiu E, Valls A, Zabaleta B, Moreno A, Pérez N. Deep morphea in a child after pneumococcal vaccination. *Indian journal of dermatology, venereology and leprology*. 2014;80(3):259.
29. Torrelo A, Suárez J, Colmenero I, Azorín D, Perera A, Zambrano A. Deep morphea after vaccination in two young children. *Pediatric dermatology*. 2006;23(5):484-7.
30. Bukhari I, Al Breiki S. Post vaccination localized morphea. *Journal of Chinese Clinical Medicine*. 2009;4(10).
31. Dursun R. Morphea DevelopIng After HepatItIs B VaccInatIon. *Selcuk Medical Journal*. 2005;21(3):83-7.
32. Matsumoto M, Yamamoto T. Pediatric generalized morphea that developed at a BCG vaccination site. *Actas dermo-sifiliograficas*. 2014;106(2):150-2.
33. Kim J, Chung KB, Lee YI, Kim J, Lee JH. Clinical characteristics and histopathologic changes of morphea: A single-center, retrospective study of 137 patients. *Journal of the American Academy of Dermatology*. 2021;85(1):105-13.
34. Leitenberger JJ, Cayce RL, Haley RW, Adams-Huet B, Bergstresser PR, Jacobe HT. Distinct autoimmune syndromes in morphea: a review of 245 adult and pediatric cases. *Archives of dermatology*. 2009;145(5):545-50.
35. Desmond BL, Blattner CM, Young III J. Generalized morphea as the first sign of breast carcinoma: a case report. *Dermatology online journal*. 2016;22(2).
36. Pappova T, Pec J, Kozarova A, Adamicova K. Cutaneous Paraneoplastic Manifestation (Morphea, Lichen Sclerosus)-Two Case Reports. *Acta Medica Martiniana*. 2017;17(1):28.
37. Grewal I, Khan O, Davis W. Squamous cell carcinoma and eosinophilia in a long-term course of pansclerotic morphea. *Case Reports*. 2014;2014:bcr2014205737.
38. Nashel J, Steen V. Scleroderma mimics. *Current rheumatology reports*. 2012;14(1):39-46.
39. Afshar ZM, Babazadeh A, Javanian M, Barary M, Rekha VVK, Ebrahimpour S. A comprehensive review of COVID-19 treatment. *Acta facultatis medicae Naissensis*. 2021;38(2):105-15.

40. Martinez-Lopez A, Cuenca-Barrales C, Montero-Vilchez T, Molina-Leyva A, Arias-Santiago S. Review of adverse cutaneous reactions of pharmacologic interventions for coronavirus disease 2019 (COVID-19): a guide for the dermatologist. *Journal of the American Academy of Dermatology*. 2020.
41. Schwartz RA, Sharma A, Lotti T, Szepietowski JC, Sandhu S, Goldust M. Systemic Medications of Dermatological Importance in COVID-19. *J Drugs Dermatol*. 2020;19:217-20.
42. Lee EY, Glassman SJ. Deep morphea induced by interferon- β 1b injection. *JAAD case reports*. 2016;2(3):236.
43. Fett N, Werth VP. Update on morphea: part II. Outcome measures and treatment. *Journal of the American Academy of Dermatology*. 2011;64(2):231-42.
44. Aryanian Z, Shojae N, Goodarzi A, Shirzadian A, Hatami P. Influence of Narrow-Band Ultra Violet B Phototherapy on Homocysteine Status: A Prospective Study of Patients with Different Cutaneous Disorders. *Photobiomodulation, Photomedicine, and Laser Surgery*. 2021;39(9):607-11.

Figures:

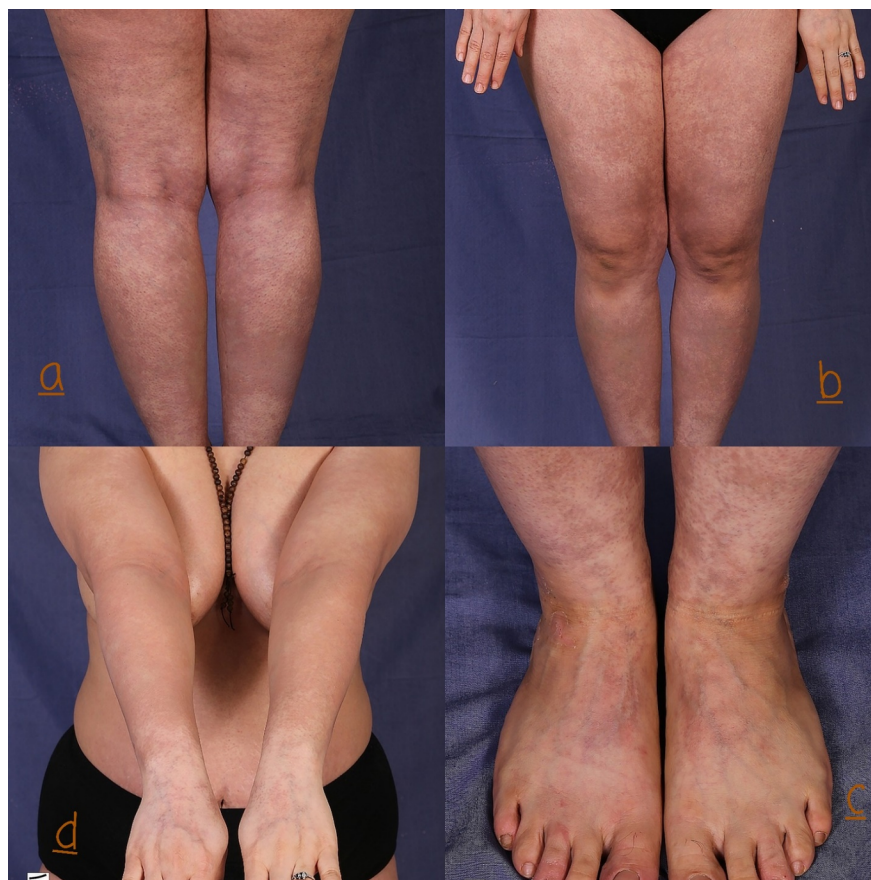


Figure 1. Generalized erythemato-sclerotic lesions (a-d) following COVID-19

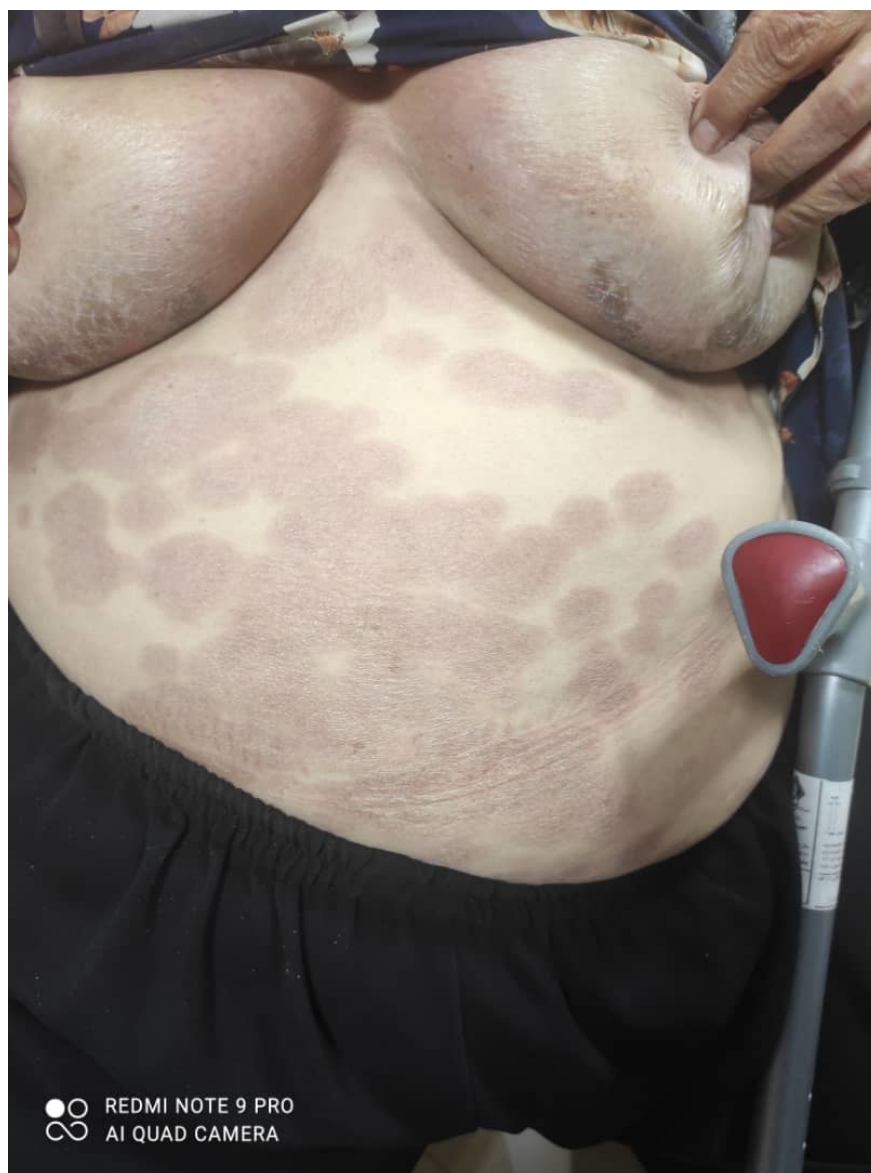

Figure 2. Multiple erythematous-violaceous and sclerotic lesions developed a few days after getting the first dose of AstraZeneca SARS-CoV-2 vaccine.