

Metastatic squamous carcinoma of cervix with tricuspid valve involvement

Yong Lei¹

¹Department of Cardiovascular Surgery Nanchong Center Hospital The Second Clinical College North Sichuan Medical College Nanchong sichuan 637000 PR China

May 10, 2022

Abstract

Background: Cervical squamous cell carcinoma is one of the most common malignant tumors in the clinic. It can metastasize to the lung, bone, and other organs. However, postoperative recurrence and metastasis to the tricuspid valve are infrequent. **Case presentation:** A 57-year-old female patient, which had an operation history of squamous carcinoma of the cervix(SCC) one year ago, was admitted to the hospital due to the cervical squamous cell carcinoma recurred and metastasized to the tricuspid anterior and septum' ventricular surface and the chordae tendineae. The patient underwent surgery in our hospital. Then the positron emission tomography-computed tomography of postoperation revealed cervical squamous cell carcinoma metastasis. Histopathology revealed the squamous carcinoma of the cervix. Moreover, the cardiac tumor reappeared after four postoperation months. The postoperative patients did not receive regular chemotherapy. The short-term effect on the patients was not ideal. **Conclusion:** To achieve better treatment results, the multi-mode treatment strategy of surgery, medical treatment, and advanced diagnosis has a significant impact on the survival of these patients.

Metastatic squamous carcinoma of cervix with tricuspid valve involvement

Yong Lei *

Department of Cardiovascular Surgery, Nanchong Center Hospital, The Second Clinical College, North Sichuan Medical College, Nanchong, sichuan 637000, PR China

*Corresponding author. Address: No. 98 Renmin south road, Shunqing district, Nanchong, Sichuan province, Tel: 18784707307, Email: zhoujy1115@foxmail.com

Abstract

Background: Cervical squamous cell carcinoma is one of the most common malignant tumors in the clinic. It can metastasize to the lung, bone, and other organs. However, postoperative recurrence and metastasis to the tricuspid valve are infrequent.

Case presentation: A 57-year-old female patient, which had an operation history of squamous carcinoma of the cervix(SCC) one year ago, was admitted to the hospital due to the cervical squamous cell carcinoma recurred and metastasized to the tricuspid anterior and septum' ventricular surface and the chordae tendineae. The patient underwent surgery in our hospital. Then the positron emission tomography-computed tomography of postoperation revealed cervical squamous cell carcinoma metastasis. Histopathology revealed the squamous carcinoma of the cervix. Moreover, the cardiac tumor reappeared after four postoperation months. The postoperative patients did not receive regular chemotherapy. The short-term effect on the patients was not ideal.

Conclusion: To achieve better treatment results, the multi-mode treatment strategy of surgery, medical treatment, and advanced diagnosis has a significant impact on the survival of these patients.

Keywords: squamous carcinoma of cervix, tricuspid valve, recurrence, metastasis

Background

Metastatic cardiac tumors are rare clinically. Furthermore, the lack of specific clinical manifestations makes it challenging to diagnose and distinguish them clinically, so the diagnosis and treatment of metastatic heart tumors face significant challenges for surgeons [1]. We hope to share the case that could help in the clinical treatment of metastatic cardiac tumors.

Case presentation

A 57-year-old female patient detected masses on the tricuspid valve's ventricular surface by transthoracic echocardiography(TTE). The patient had a medical history of squamous carcinoma of the cervix(SCC) one year ago when the TTE was no abnormality. On physical examination, vital signs were stable with a blood pressure of 100/64 mmHg, a heart rate of 79 b.p.m, and a respiratory rate of 18 per minute. Laboratory examination proved mild anemia. It slightly elevated the counts of C-reactive protein(CRP), erythrocyte sedimentation rate(ESR), D-dimer (turbidimetry), and fibrinogen degradation products(FDP). Transthoracic echocardiography showed a mobile mass on the tricuspid ventricular surface protruding into the pulmonary valve during systole (Fig 1A, marks) and many neoplasms attaching the tricuspid valve and its chordae tendineae(Fig 1B, arrow). The imaging showed no sign of pulmonary emboli. Considering the high risk of the lump falling off, the patient underwent a one-stage operation through median sternotomy to establish cardiopulmonary bypass. A honeycomb mass (Fig 1C, arrows) was attached to the anterior tricuspid valve with a dimension of about 33mm×18mm. Moreover, many small groups were attached to the ventricular surface of the tricuspid valve and its chordae tendineae. All masses and part of the chordae tendineae were removed and reconstructed. Histopathology revealed SCC (Fig 1D, E). The enhanced positron emission tomography-computed tomography(PET-CT) showed increased glucose metabolism in the lymph nodes on the left side of the abdominal aorta and behind the foot of the left diaphragm(Fig 1F, arrows). It was supposed to originate from cervical squamous cell carcinoma recurrence and distant metastasis. Furthermore, the TTE found no abnormality (Fig 2A), electrocardiogram, and PET-CT(Fig 2 B, arrows) after the operation on the heart. The patient recovered successfully postoperative course. However, the postoperative patients did not receive regular chemotherapy. One month after the procedure, the color Doppler Echocardiography showed normality in color Doppler Echocardiography(Fig 2C, arrow).

Three months after discharge, the patient has admitted again because he found a mass in the left neck with a dimension of about 22mmx30mm, which was hard, with poor mobility, and no tenderness. Color Doppler ultrasonography of cervical lymph nodes revealed hypoechoic nodules in the left neck, considering lymph node growth and structural abnormalities. The 64-slice Spiral Computed Tomography of the chest showed left supraclavicular fossa and axillary multiple lymph nodes with partial enlargement. The patient underwent left cervical mass resection. The pathological examination showed metastatic squamous cell carcinoma of lymph nodes (Fig 2D, arrow) and tumor thrombus (Fig 2E, arrow). After the operation, the patient was successfully discharged from the hospital but still did not receive traditional chemotherapy. Next, the TTE revealed a mass attached to the tricuspid valve with a dimension of about 28.1mmx18.2mm(Fig 2F, arrow). There is no noticeable change in examining the 64-slice Spiral Computed Tomography of the chest and electrocardiogram compared with last time. According to the current condition of the patients, the short-term effect after the operation is not ideal, and the progress of the patient's condition still needs further follow-up.

Discussion

Clinically, tumor metastasis to the heart is rare and often ignored. Patients with cardiac masses with a history of a tumor should considered. TTE is usually the first examination to identify intracardiac groups. However, cardiac imaging techniques, such as PET-CT, can accurately determine the nature of cardiac

masses and the invasion of pericardial structures, which is a fundamental step in guiding clinical surgical and non-operative treatment strategies.

There is no doubt about whether metastatic heart tumors should remove. Surgery is essential for treating cardiac tumors^[2] and the first choice for all cardiac tumors^[3]. As reported in the literature^[4,5], cardiac surgery is very effective for benign cardiac tumors and most malignant tumors (primary or secondary). It can solve the potentially and rapidly life-threatening situations associated with heart disease. Besides, cardiac surgery and cardiopulmonary bypass have no adverse effects on the survival of patients with malignant tumors^[6] and can achieve low early mortality and excellent survival rate^[7].

However, the patient did not receive formal medical treatment, so cervical squamous cell carcinoma metastasized to the left cervical lymph node and recurrence in the valvula tricuspidalis. The treatment of metastatic cardiac tumors is not a single mode of medicine but a combination of surgery, medical treatment, and advanced diagnosis, which may significantly impact the survival of these patients^[8,9].

Conclusion

To achieve better treatment results, the multi-mode treatment strategy of surgery, medical treatment, and advanced diagnosis has a significant impact on the survival of these patients.

Abbreviations

TTE	transthoracic echocardiography
SCC	squamous carcinoma of the cervix
CRP	C-reactive protein
ESR	erythrocyte sedimentation rate
FDP	fibrinogen degradation products
PET-CT	positron emission tomography-computed tomography

Ethical Approval and Consent to participate The case are compliance with ethical standards and consented for publication.

Consent for publication The patient had consented for publication.

Availability of data and materials It is truth and availability of data and materials.

Competing interests The author declare they have no conflicts of interest.

Funding This study was supported in part by the following funding sources: The Youth Projects (Natural Sciences) of The North Sichuan Medical College(Project number: CYB21-QA19).

Authors contributions The author are involved in the writing of the manuscript.

Acknowledgments We are grateful to Yongmei Nie in Key Laboratory of Cardiovascular and Metabolic of Luzhou City at Affiliated Hospital of Southwest Medical University,Yanhua Li in Department of Doppler Ultrasonic and Xiaoguang Guo in Department of pathology of Nanchong Center Hospital to offer the pictures.

References

1. Lichtenberger, JP; Carter, BW; Pavio, MA; Biko, DM. Cardiac Neoplasms: Radiologic- Pathologic Correlation.Radiol Clin North Am.2021 Mar ;59(2):231-242.
2. Thorac Cancer. 2020 Nov;11(11):3060-3070. doi: 10.1111/1759-7714.13651.
3. Janus, SE; Al-Kindi, SG; Rashid, I; Hoit, BD.Cystic left ventricular mass: the utility of transthoracic echocardiography and cardiac MRI.BMJ Case Rep.2021 Feb 26 ;14(2)
4. Cardiac tumours: diagnosis and management, Heart 97 (2) (2011) 151–160.
5. G.H. Oliveira, S.G. Al-Kindi, C. Hoimes, C.Park, S.J. Characteristics and survival of malignant cardiac tumors: a 40-year analysis of > 500 patients, Circulation 132 (25) (2015) 2395–2402.

6. Fu, Q.Li, QZ.Liang, DG.Ruan, XH.Wang, ZX.Wei, MX.Early and long-term results of combined cardiac surgery and neoplastic resection in patients with concomitant severe heart disease and neoplasms.Chin Med J (Engl).2011V124N13:1939-42.
7. Vuković, PM.Milojević, PS.Perić, MS.Gradinac, SD.Mićović, SV.Cirković, MV.Borović, SD.Labudović-Borović, M.Djukanović, BP.Cardiac neoplasms: results of the surgical treatment between 2000. and 2008.Acta Chir Jugosl.2009V56N2:23-6.
8. Rahouma, M.Arisha, MJ.Elmously, A.El-Sayed Ahmed, MM.Spadaccio, C.Mehta, K.Baudo, M.Kamel, M.Mansor, E.Ruan, Y.Morsi, M.Shmushkevich, S.Eldessouki, I.Rahouma, M.Mohamed, A.Gambardella, I.Girardi, L.Gaudino, M.Cardiac tumors prevalence and mortality: a systematic review and meta-analysis.Int J Surg.2020V76N:178-189.
9. Cancer Med. 2021 May;10(10):3449-3460. doi: 10.1002/cam4.3857.15-Dec-2021.

Figure

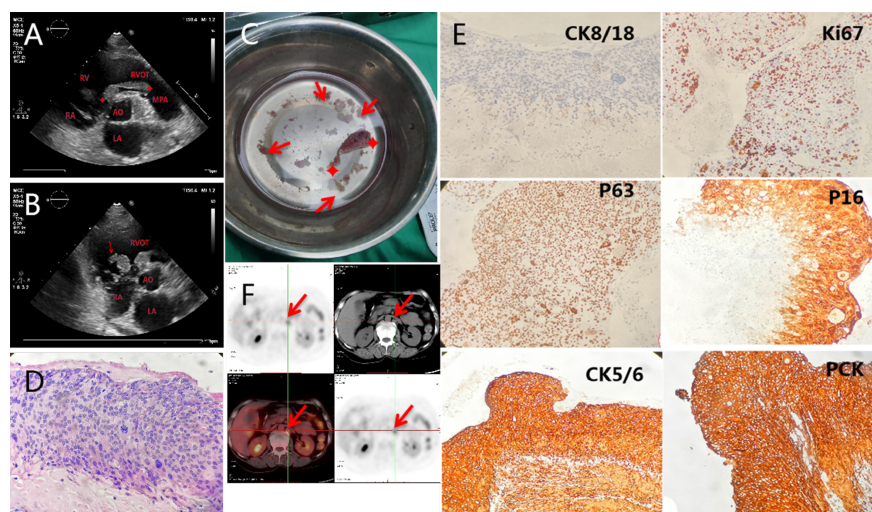


Fig 1 A: Transthoracic echocardiography showed a mass on the tricuspid ventricular surface, which protruded into the pulmonary valve during systole and many neoplasms attached to the tricuspid valve and its chordae tendineae(**B**). **C:** Intraoperative resection of the masses.**D:** Pathological section indicated neoplastic lesion, which was considered as carcinoma.**E:** Immunohistochemical diagnosis was squamous cell carcinoma.**F:** PET-CT revealed increased glucose metabolism in the lymph nodes on the left side of the abdominal aorta and behind the foot of the left diaphragm. CK8/18:cytokeratin8/18,Ki67:Tumor proliferative antigen, P63,P16: tumor suppressor gene,CK5/6: cytokeratin5/6,PCK:Pan Cytokeratin.

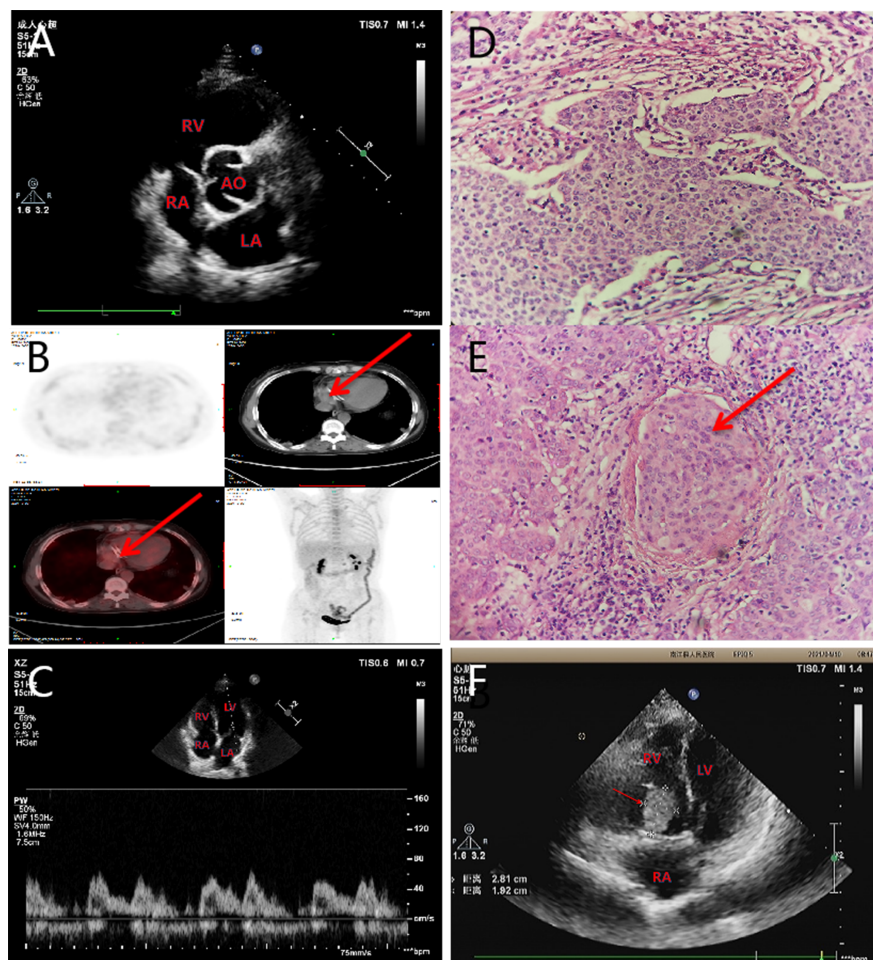


Fig 2 A: No abnormality was found in transthoracic echocardiography and PET-CT(**B**) after the operation in the heart(Tricuspid valve forming ring,arrows). **C:** There was no abnormality in cardiac color Doppler ultrasonography after one operation month. **D:** Pathological section showed metastatic squamous cell carcinoma of lymph nodes and saw tumor thrombus (**E**). **F:** Echocardiography revealed that a mass was attached to the tricuspid valve after four heart surgery months.

