

Successful drainage of periaortic graft abscess and transcatheter aortic valve replacement in the same setting - a hybrid approach.

Ahmed S. Nasser¹, Osama Elkhateeb², Keir Stewart³, and Hashem Aliter³

¹Dalhousie University Faculty of Medicine

²Dalhousie University Department of Medicine

³Dalhousie University Division of Cardiac Surgery

June 16, 2022

Abstract

81-year-old man with a history of Bio-Bentall surgery presented to the emergency department with fever, chills and back pain. Initial physical examination was inconclusive apart from sudden onset of delirium, and investigation showed elevated WBCs, anemia, and neutrophilia. Further studies revealed gram-positive cocci on the initial blood culture, which was then confirmed to be MSSA bacteremia. Subsequently, a TEE showed a peri-aortic abscess, Moderate AR and severe AS with no evidence of endocarditis. Antibiotics were started and urgent abscess drainage was planned. In a hybrid operative setting, a multidisciplinary team of cardiology, and cardiac surgery managed the periaortic graft abscess drainage through a median sternotomy and TAVR. Post-operatively, the complications included bradycardia, and RHF. Six-week course of IV Rifampin, Probenecid and Cefazolin was initiated, and patient was to remain on lifelong Cefadroxil.

TITLE: Successful drainage of periaortic graft abscess and transcatheter aortic valve replacement in the same setting - a hybrid approach.

Running title: Hybrid approach to periaortic abscess.

AUTHORS: Ahmed S. Nasser M.D. ^a, Osama El Khateeb M.D. ^b, Keir Stewart M.D. ^c, Hashem Aliter M.D., Ph.D. ^c

AFFILIATIONS:

^a Dalhousie University, Halifax, NS, Canada.

^b Division of Cardiology, Department of Medicine, Dalhousie University, Halifax, NS, Canada.

^c Division of Cardiac Surgery, Department of Surgery, Dalhousie University, Halifax, NS, Canada

Conflicts : The authors have nothing to disclose.

Funding: None of the authors received grants, contracts, or financial support.

Consent: Patient consent was taken for this report.

Hospital Ethics board approval was granted for this report.

Total word count: 1170 (body), 1561 (all inclusive).

CORRESPONDING AUTHOR:

Ahmed S. Nasser

Address for correspondence

QEII Health Science Center, Dalhousie University.

Room 3261, Victoria Building, 1276 South Park Street, Halifax, NS B3H 2Y9.

Tel: (902) 440 8644

Ahmed.nasser@dal.ca

ABSTRACT

81-year-old man with a history of Bio-Bentall surgery presented to the emergency department with fever, chills and back pain. Initial physical examination was inconclusive apart from sudden onset of delirium, and investigation showed elevated WBCs, anemia, and neutrophilia. Further studies revealed gram-positive cocci on the initial blood culture, which was then confirmed to be MSSA bacteremia. Subsequently, a TEE showed a peri-aortic abscess, Moderate AR and severe AS with no evidence of endocarditis. Antibiotics were started and urgent abscess drainage was planned. In a hybrid operative setting, a multidisciplinary team of cardiology, and cardiac surgery managed the periaortic graft abscess drainage through a median sternotomy and TAVR. Post-operatively, the complications included bradycardia, and RHF. Six-week course of IV Rifampin, Probenecid and Cefazolin was initiated, and patient was to remain on lifelong Cefadroxil.

KEYWORDS

Aortic valve replacement, hybrid operating room, aortic graft infection, TAVR.

HISTORY OF PRESENTATION

An 81-year-old male with a history of Bio-Bentall procedure performed 13 years ago presented to the emergency department with the chief complaints of fever, chills, and flank pain. The patient was previously an active individual who acutely developed symptoms of bilateral flank pain, weakness, fever, and chills a week before admission, and nausea with no vomiting two days prior to admission. Upon examination, vital signs were stable and there were no other significant findings on systematic review.

PAST MEDICAL HISTORY

Patients' medical history was relevant for a surgically repaired ascending aorta aneurysm using a 30 mm Gelweave graft and aortic valve replacement with a 23 mm CE pericardial tissue valve (Edwards Lifesciences, Irvine, CA, USA) with reimplantation of coronary arteries. The patient also had underlying hypertension, and aortic pseudo-coarctation (**Figure 1A**), prostate cancer, and chronic atrial fibrillation.

DIFFERENTIAL DIAGNOSIS

Kidney stone, acute pyelonephritis, septic pulmonary emboli, and infective endocarditis were part of the differential diagnosis.

INVESTIGATION

The patient's blood work showed leukocytosis, normocytic anemia, elevated creatinine, and the presence of RBCs, nitrites, and proteins on urinalysis. A chest X-ray ruled out any lung pathologies. A CT chest (**Figure 2B**), abdomen and pelvis ruled out renal or pulmonary pathologies and was started on Ceftriaxone 1g IV. Initial blood culture revealed gram-positive cocci for which Piperacillin-Tazobactam 3.375g q6h IV (Pip-Tazo) was added to the treatment. Subsequently, the blood cultures showed Methicillin Sensitive Staph Aureus (MSSA) bacteremia and therapy was changed to Vancomycin 2g IV loading dose followed by 1250mg IV q12h and Cefazolin 2g IVq8h. The patient had a transthoracic echocardiogram (TTE) which demonstrated moderate aortic regurgitation and severe aortic stenosis with bi-atrial enlargement. However, the transesophageal echocardiography (TEE) showed a well loculated large area of echo-dense material around the aortic valve consistent with a peri-aortic abscess (**Figure 2A**) with no evidence of endocarditis. Cardiac catheterization was normal.

MANAGEMENT

Patient was admitted to the Internal medicine floor and Infectious diseases team were consulted, they concurred with the current treatment plan of Cefazolin and Vancomycin. After the TEE findings and normal cardiac catheterization, we decided to move forward with surgery. Due to the patient's co-morbid status, Euro score of 15% and high mortality risk, it was deemed that the surgery should take place in a hybrid operating room setting. The patient underwent surgery - a redo-sternotomy in the standard fashion - and a large abscess cavity was seen surrounding the aortic graft. Following the abscess drainage, the cavity was washed with antibiotic solution with placement of antibiotic beads around the graft, and the sternum was closed. The bacterial culture of pus and tissue collected during the surgery was negative.

The heart team performed a Trans Catheter Aortic Valve Implantation (TAVI) valve in valve procedure (**Figure 1B**) and (**Video 1**) . A 14 French pro-glide sheath and a 6 French pro-glide sheath were used in the right and left femoral arteries respectively. A Medtronic CoreValue Evolut R 26 mm valve (CoreValve, Medtronic, Luxembourg) was used. Post-operative ECHO showed a well-seated aortic valve with a mean gradient of 8 mmHg and no leaks noted (**Figure 2C**) and (**Video 2**) .

Postoperatively, the patient's recovery was complicated with right heart failure (RHF) and symptomatic bradycardia that resolved. It was decided that the patient will remain on lifelong suppressive antibiotic therapy with daily Cefadroxil 1gm orally.

FOLLOW-UP

After six months, a routine follow-up ECHO showed a normally functioning bioprosthetic valve with a slightly increased thickness of the aortic root that was presumed to be secondary to the inflammatory process from debridement of the abscess. No stenosis or regurgitation was seen, and LV and RV systolic functions were normal.

DISCUSSION

Infections of the aortic grafts are rare postoperative complications of aortic surgeries. They could happen in the early postoperative course or, as in our case, later years after surgery. Although the incidence varies between 1-5% based on center and surgeon expertise, the condition can be challenging and associated with a high mortality rate^[1, 2]. Due to its complexity and rarity, the predisposing factors for aortic graft infection are yet to be extensively identified by studies^[3]. Although the source of graft infection following the cardiac surgery procedure remains unknown, skin flora is considered the most common source of infection^[3]. Early postoperative infections are considered from direct skin flora contamination, whereas delayed infection might be due to hemostatic agents, nosocomial septicemia, and immunocompromised states^[4]. In our case the most likely predisposing factor for the patient was the immunocompromised state secondary to the treatment of prostate cancer.

Symptoms of aortic graft infection are often vague, and this requires a high degree of suspicion from the clinician when treating patients with pre-existing aortic grafts. It could present as a myriad of vague symptoms, including: fever, malaise, weight loss, back pain, leukocytosis, or abdominal pain. Computerized tomography (CT) with contrast enhancement is the diagnostic modality of choice in aortic graft infections^[5].

The EuroScore is a simple and quick way to assess patients' risk of mortality. Our patient had a score of 15%, which directly correlates to a 15% chance of postoperative death. Our patient also had multiple risk factors such as advanced age, urgent nature of procedure and history of previous cardiac surgery and anemia. Although anemia is not part of the EuroScore, studies have noted an increased mortality associated with pre-operative anemia especially in the setting of open heart surgery^[6]. Our patient was managed in a hybrid operating room setting, where the patient first underwent drainage of their peri-aortic abscesses in a surgery that carries a mortality risk ranging between 19 to 25%. Subsequently, they underwent a TAVR. Post-operatively, the patient was transferred to Cardiovascular ICU and managed in the standard fashion.

The surgical management of acute graft infection depends on the degree and extent of infection. The general belief is that if the graft and autologous tissue were still surrounded by healthy tissue, the survival rate was higher if the vascular prosthesis was not removed^[3, 7]. In our case, the graft was not infected, there were no signs of endocarditis and existing prosthetic grafts could be salvaged, so only local debridement was performed followed by placement of antibiotic beads around the graft site.

As previously mentioned, TAVR has become a game changer in the field of aortic valve surgery and thanks to this approach we were able to successfully treat a critically ill patient in a multi-disciplinary setting.

CONCLUSION

Even though graft infection rates are very low, they carry a high risk of morbidity and mortality due to the surgical nature of the procedure and risk of infection. This case report highlights that a streamlined and strong interdisciplinary approach can minimize the risk of intra and post-operative death in high-risk patients. Additionally, this report further strengthens the existing data on importance of Valve in Valve TAVR for moderate to extremely high-risk patients and enumerates the importance of considering and implementing a hybrid approach for patients with high mortality risks in the field of cardiovascular medicine as it offers the best available combination of treatments.

REFERENCES

1. K. Laohapensang, S. Arworn, S. Orrapin, T. Reanpang, and S. Orrapin, "Management of the infected aortic endograft," *Seminars in Vascular Surgery*, vol. 30, no. 2-3, pp. 91-94, Jun. 2017, doi: 10.1053/j.semvascsurg.2017.11.001.
2. R. O. Darouiche, "Treatment of Infections Associated with Surgical Implants," *N Engl J Med*, vol. 350, no. 14, pp. 1422-1429, Apr. 2004, doi: 10.1056/NEJMra035415.
3. T. Shiraev *et al.*, "Incidence, Management, and Outcomes of Aortic Graft Infection," *Annals of Vascular Surgery*, vol. 59, pp. 73-83, Aug. 2019, doi: 10.1016/j.avsg.2019.01.027.
4. E. Ducasse, A. Calisti, F. Speziale, L. Rizzo, M. Misuraca, and P. Fiorani, "Aortoiliac Stent Graft Infection: Current Problems and Management," *Annals of Vascular Surgery*, vol. 18, no. 5, pp. 521-526, Sep. 2004, doi: 10.1007/s10016-004-0075-9.
5. P. Rossi *et al.*, "Prosthetic Graft Infection: Diagnostic and Therapeutic Role of Interventional Radiology," *Journal of Vascular and Interventional Radiology*, vol. 8, no. 2, pp. 271-277, Mar. 1997, doi: 10.1016/S1051-0443(97)70554-2.
6. M. Ranucci, U. Di Dedda, S. Castelvechio, L. Menicanti, A. Frigiola, and G. Pelissero, "Impact of Pre-operative Anemia on Outcome in Adult Cardiac Surgery: A Propensity-Matched Analysis," *The Annals of Thoracic Surgery*, vol. 94, no. 4, pp. 1134-1141, Oct. 2012, doi: 10.1016/j.athoracsur.2012.04.042.
7. P. Tossios *et al.*, "Treatment of Infected Thoracic Aortic Prosthetic Grafts with the In Situ Preservation Strategy: A Review of its History, Surgical Technique, and Results," *Heart, Lung and Circulation*, vol. 23, no. 1, pp. 24-31, Jan. 2014, doi: 10.1016/j.hlc.2013.09.001.

LEGEND

ABBREVIATIONS

Transthoracic echocardiogram (TTE), Transesophageal echocardiography (TEE), Trans Catheter Aortic Valve Implantation (TAVI), Transcatheter Aortic Valve Replacement (TAVR), Echocardiogram (ECHO), Right heart failure (RHF), RV (Right ventricle), LV (left ventricle)

FIGURE TITLES AND CAPTIONS

Figure 1 A. Pseudo-coarctation of the tortuous thoracic aorta just distal to the arch. **B.** TAVR valve in valve.

Figure 2 A. TEE showing aortic root abscess (white arrow marks). **B.** Coronal CT showing aortic root abscess (white arrow mark). **C.** Post-op ECHO showing no paravalvular

leaks.

Video 1: TAVR - valve in valve procedure.

Video 2: Follow-up ECHO four months post-operative.

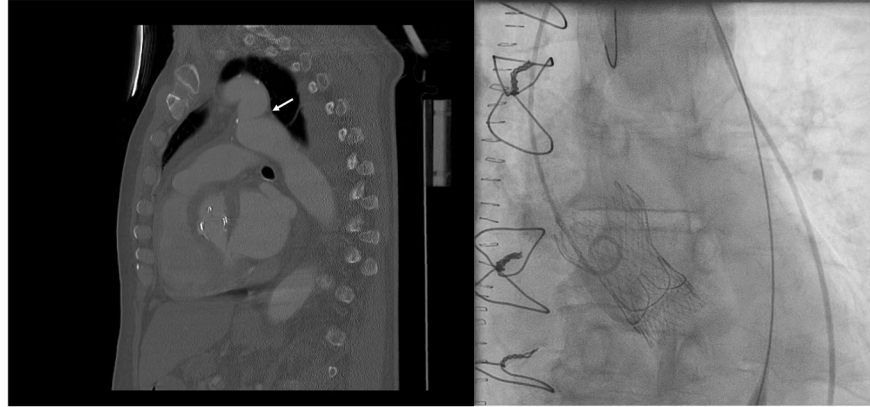


Figure 1A. Pseudo-coarctation of the tortuous thoracic aorta just distal to the arch.

Figure 1B. TAVR valve in valve.

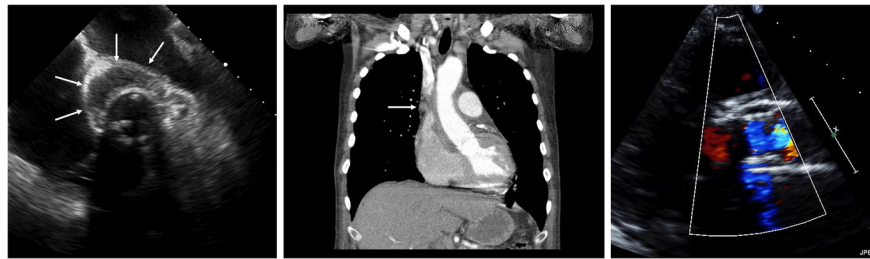

Figure 2A. TEE showing aortic root abscess (white arrow marks).

Figure 2B. Coronal CT showing aortic root abscess (white arrow mark).

Figure 2C. Post-op ECHO showing no paravalvular leaks.

Hosted file

Video 1.mp4 available at <https://authorea.com/users/489623/articles/573274-successful-drainage-of-periaortic-graft-abscess-and-transcatheter-aortic-valve-replacement-in-the-same-setting-a-hybrid-approach>

Hosted file

Video 2.mp4 available at <https://authorea.com/users/489623/articles/573274-successful-drainage-of-periaortic-graft-abscess-and-transcatheter-aortic-valve-replacement-in-the-same-setting-a-hybrid-approach>