

# Actinomycetoma distal radius mimic osteosarcoma, case report of rare presentation.

Hassan Elbahri<sup>1</sup>, Adnan Alnaser<sup>2</sup>, Sawsan Babiker<sup>3</sup>, and Alaa Mohamed<sup>3</sup>

<sup>1</sup>International University of Africa

<sup>2</sup>University of Gezira Faculty of Medicine

<sup>3</sup>University of Khartoum Faculty of Medicine

July 28, 2022

## Abstract

Various conditions may mimic osteosarcoma. The differential diagnosis of osteosarcoma is broad. A proper history, examination, diagnostic imaging studies, and pathological analysis are essential to establish the precise diagnosis. This case report serves to illustrate the significance of recognizing similarities and other rare features to prevent late or misdiagnosis.

## Introduction

Osteosarcoma is commonest primary malignant bone tumor of unintelligible origin, with peak age at 10-19 years old(1). The distal radius is a rare site for osteosarcoma; it was reported less than <1% (2). Between all the bone tumors, osteosarcoma have the widest variety in clinical presentation, imaging findings, morphological and histological features. The mainstream treatment is combination of chemotherapy and surgical treatment which improved the overall prognosis in the last two decades (3-4). However, mycetoma is a chronic cutaneous and subcutaneous painless swelling caused by two major types of pathogens, either bacterial type (actinomycotic) or fungus type (eumycotic) [5]. It is the most common neglected disease of human in tropical and subtropical areas among low socioeconomic individuals [5,6]. It involves the skin and connective tissue. Painless destructive nature, late presentation, poor response to treatment and high recurrence rate are characteristic features of this disease. Among all the endemic countries, Sudan have the highest incidence [6-8]. The chronic inflammatory granuloma, various deformities, disabilities and high morbidity rate are the commonest known complications of mycetoma, the disease can be potentially limb threatening in its late stage [9,10]. Clinically, mycetoma starts as a small painless lump which increase in size gradually, forming multiple sinuses with seropurulent discharge and eventually multicolored grains appear [11]. Meticulous Clinical assessment , radiological and histopathological analysis of such lesion is important for a precise diagnosis and management, especially when dealing with unclear osteo-articular lesion. Management of mycetoma predominantly depends on the etiological agent, site and extent of the disease [12]. This case review serves to exemplify the importance of recognizing the similarities between these 2 lesions and other rare features that will help differentiate between osteosarcoma and mycetoma, also to highlight and demonstrate the destructive features of bone involvement by mycetoma that usually associate with inadequate assessment, and the impact of delayed presentation or late diagnosis to the overall outcome.

## Case presentation

A 40 year old female farmer from Sudan referred to our orthopedic oncology clinic at Ibrahim Malik Teaching Hospital –Sudan, complaining of chronic right distal forearm pain, swelling and numbness for two years, it started with small painless lump that over period of time increased in size gradually, recently her quality of life and functional status had been massively affected due to increasing pain intensity, increase symptoms

anguish and constant decrease in range of motion at the wrist joint. Patient were ill but not pale, no loss of weight neither constitutional symptoms were noted, vital signs were within normal range. No Sinuses were noted throughout the course of presentation. Conventional xray show right distal radius mixed lytic and sclerotic bone lesion with sunburst periosteal reaction and soft tissue swelling [fig1] . Initially and with inadequate assessment, she was suspected with osteosarcoma distal radius, thus she was referred. No advance imaging requested, or biopsies were taken. Since then the deterioration in her general condition had been growing steadily. Painful activity of daily living agonized the patient, swelling and limitation of movement on the affected side had been worsening dramatically. Furthermore she ended by using daily pain killer for long time. On clinical examination there was obvious right distal forearm swelling and tenderness mainly at the radial and dorsal side of the forearm, the mass was irregular in shape, hard in consistency measured about 7\*3 cm, with mild temperatures asymmetry compared with adjacent skin, no sinuses were identified lymphatic streaks. Hematological investigations were unremarkable, X-ray revealed the same findings and MRI of right wrist show right distal forearm swelling (enhancement) incasing distal neurovascular bundle , pre-tumor edema , no skip lesions[fig2-3]. CT chest & chest X-ray were normal, no evidence of metastases. At this point the decision was to take core biopsy under general anesthesia. Histopathology analysis reports multiple grains of streptomyces somaliensis surrounded by granulation tissues with gaint cell granuloma, the features of actinomycetoma consistent with streptomyces somaliensis[fig4] . Second surgery i.e. wide local excision and fixation was done and second biopsy were taken, confirming the diagnose.

After two months from operation the patient's condition improved and referred to mycetoma center in Soba hospital for medications [fig5] .

## Discussion and conclusion

Actinomycetoma Osteomyelitis radius is very rare condition to be reported. Destructive bone pattern by mycetoma species, in situ grains formation and Unequivocal distinction between actinomycetoma and various manifestations of osteosarcoma either in painful event or numbness at late stage are extremely rare findings to be seen, also the unique periosteal reaction in form of sunburst ray appearance can also be the source of significant diagnostic challenges, when it happens the risk of limb loss by amputation will be very high. Initial Painless nature of the lesion, low socioeconomic status and low level of education are the reason drives Sudanese patients to present late.

As mentioned above the treatment of mycetoma predominantly depends on the infective agent, site and extent of infection[12]. Until recently in Sudan, amputation was the only available treatment for mycetoma, as extremely high recurrence rate prevent optimum therapeutic results to be reached.

Actinomycetoma (bacterial type) is usually treated with medications only as it shows relative response to medical treatment in early stages. For fungal type (eumycetoma), a combination of aggressive surgical and medical treatment (anti-fungal agents) are the gold standard as drug resistant prevent solely medical treatment [13].

Actinomycetoma infective agents are difficult to confirm. Hence, accurate assessment should include proper clinical history and examination, radiological evaluation by expert radiologist and Orthopedist, pathological analysis of the affected area with a Tru-Cut needle biopsy and immunohistochemistry to avoid problems of inadequate specimens commonly associated with incisional biopsy [14]. Overall outcome can be optimized significantly after precisely identification of the causative organism and extended post treatment follow up.

Unfortunately due to the late presentation, aggressive features of bone and surrounding structures Invasion found in our patient and fear of high recurrence rate, surgical approaches in combination with

Medical treatment were decided. Many Sudanese patients undergo many operations with several Prolonged medical regimens to enable adequate response. Nevertheless, surgical options for mycetoma Treatment in Sudan range from wide local excision to amputation of the affected limb, correct wide local Excision and bloodless field by expertise during surgery are paramount essential to excellence the Outcome [15].

The post treatment recurrence rate is high, range between 25-50%. Age, duration, site and extent of In-

involvement and previous history of mycetoma recurrence are predictors of overall outcome. Thereby, Surgical operation considers the best treatment option to minimize the risk of recurrence especially if Done properly as mentioned above[16].

Surgical intervention unfortunately associates with high rate of morbidity and disability among Mycetoma patients in Sudan. Postoperative extended follow up, physiotherapy of the nearby joints and Adherence to antibiotics regimen regarding to the protocol are essential for better clinical and functional Outcomes and to avoid the permanent disabilities.(17)

In conclusion, actinomycetoma Osteomyelitis radius is rare condition. Clinicians in endemic areas must Consider mycetoma osteomyelitis as a differential diagnosis when they are dealing with vague atypical Musculoskeletal destructive lesions. Multidisciplinary team and Triple assessment including clinical, Radiological and histopathological correlation are extremely important to prevent misdiagnosis, surgical Treatment in combination with medical treatment followed by regular clinical and radiological follow up Can be limb saving procedure in such cases. Finally, treatment of mycetoma osteomyelitis cases is case By case individually according to the predictors of post-operative recurrence.(17)

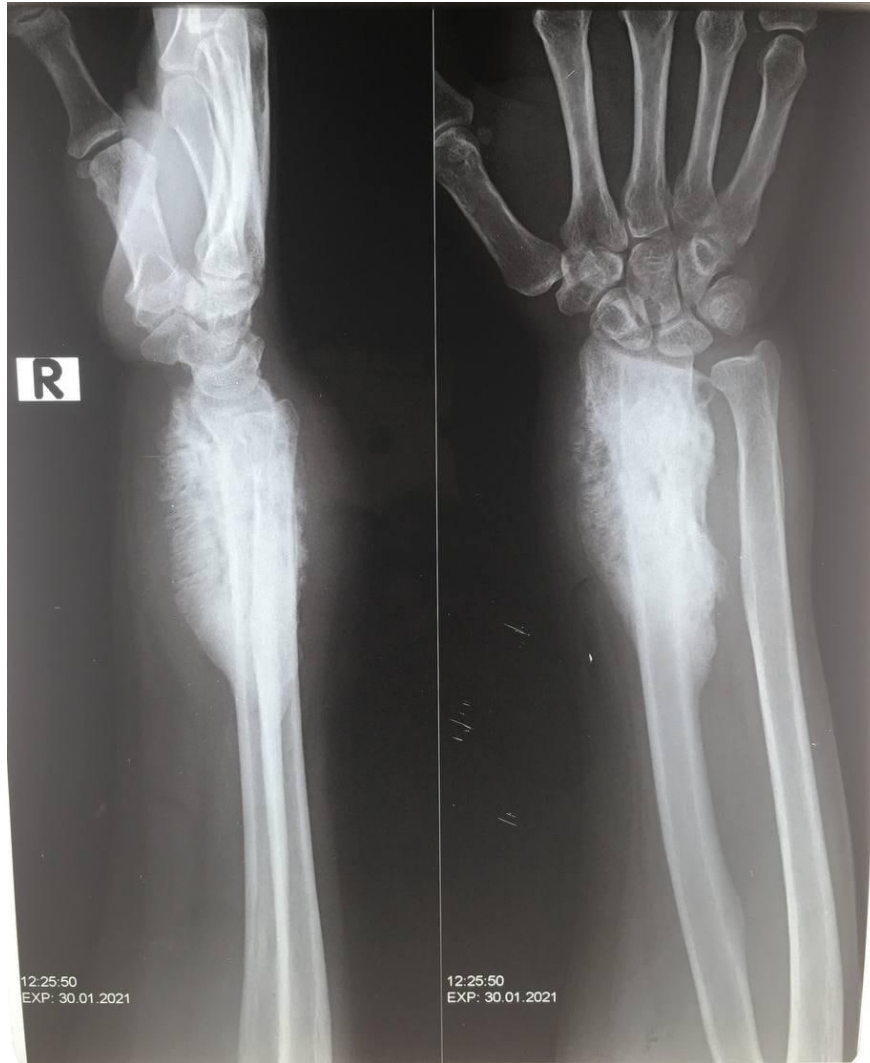## Reference

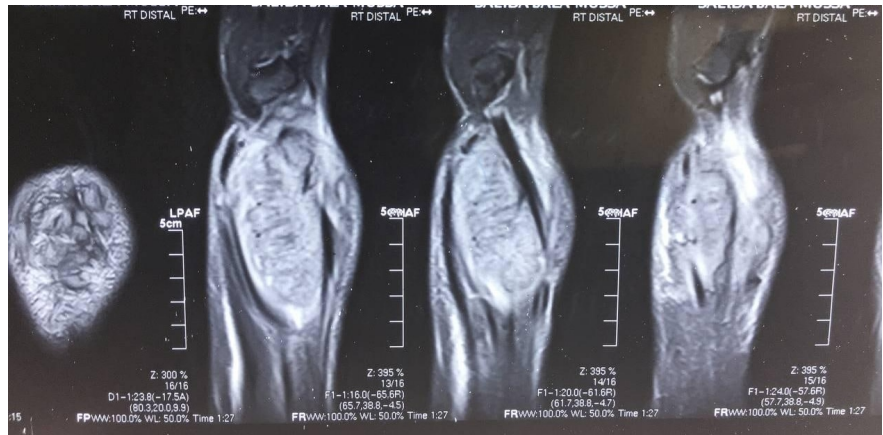
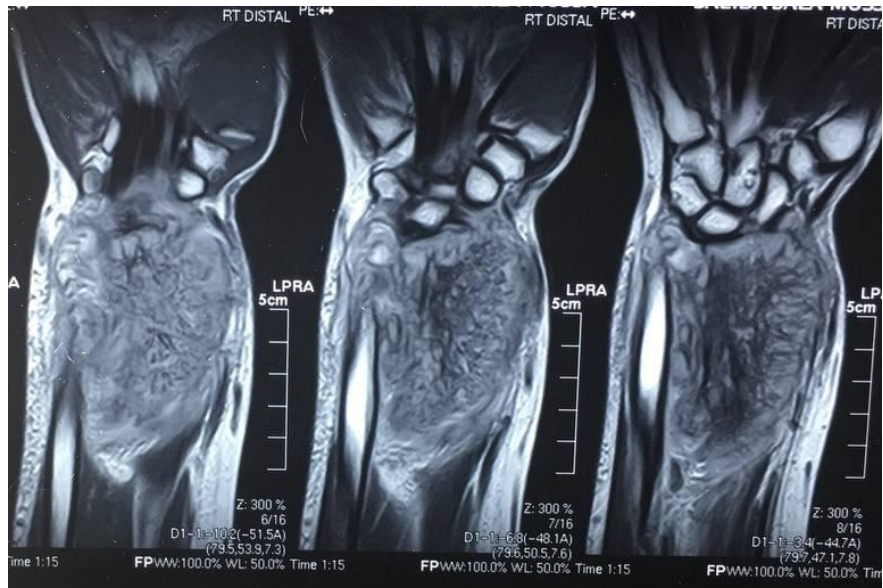
- 1.Messerschmitt PJ, Garcia RM, Abdul-karim FW, Greenfield EM, Getty PJ. Osteosarcoma. J Am Acad Orthop Surg. 2009;17:515–527.
- 2.Unni KK, editor. Dahlin's Bone Tumors: General Aspects and Data on 11,087 Cases. 5<sup>th</sup> edition. Lippincott-Raven; Philadelphia, PA: 1996. Pp. 143–183.
3. Wadhwa N. Osteosarcoma: Diagnostic dilemmas in histopathology and prognostic factors. Indian Journal of orthopaedics. 2014 Jun;48(3):247-54.
- 4.Eckardt JJ, Grogan TJ. Giant cell tumor of bone. Clin Orthop Relat Res. 1986;204:45–58.
- 5.Zijlstra EE, Van De Sande WW, Fahal AH. Mycetoma: a long journey from neglect. PLoS Negl Trop Dis. 2016;10(1):e0004244.
- 6.Develoux M, Dieng MT, Kane A, Ndiaye B. Management of mycetoma in West-Africa. Bull Soc Pathol Exot. 2004;96(5):376–82.
- 7.Fahal AH. Mycetoma thorn on the flesh. Trans R Soc Trop Med Hyg. 2004;98(1):3–11.
- 8.Fahal AH, Hassan MA. Mycetoma. Br J Surg. 1992;79(11):1138–41.
- 9.Bonifaz A, Tirado-Sánchez A, Calderón L, Saúl A, Araiza J, et al. Mycetoma: experience of 482 cases in a Single center in Mexico. PLoS Negl Trop Dis. 2014;8(8):e3102.
- 10.Ahmed AO, van Leeuwen W, Fahal A, van de Sande W, Verbrugh H, et al. Mycetoma caused by *Madurella mycetomatis*: a neglected infectious burden. Lancet Infect Dis. 2004;4(9):566–74.
- 11.Nenoff P, van de Sande WW, Fahal AH, Reinell D, Schöfer H. Eumycetoma and actinomycetoma—an Update on causative agents, epidemiology, pathogenesis, diagnostics and therapy. J Eur Acad Dermatol Venereol. 2015;29(10):1873–83.
- 12.Welsh O, Al-Abdely HM, Salinas-Carmona MC, Fahal AH. Mycetoma medical therapy. PLoS Negl Trop Dis. 2014;8(10):e3218.
- 13.Abd El Bagi ME. New radiographic classification of bone involvement in pedal mycetoma. AJR Am J Roentgenol. 2003;180(3):665–8.
- 14.Ahmed AA, van de Sande W, Fahal AH. Mycetoma laboratory diagnosis: Review article. PLoS Negl Trop Dis. 2017;11(8): e0005638.

15. Bakhiet SM, Fahal AH, Musa AM, Mohamed ESW, Omer RF, Ahmed ES, El Nour M, Mustafa ERM, Sheikh A, Rahman ME, Suliman SH, El Mamoun MAG, El Amin HM. A holistic approach to the mycetoma Management. *PLoS Negl Trop Dis.* 2018;12(5):e0006391.

16. Wadal A, Elhassan TA, Zein HA, Abdel-Rahman ME, Fahal AH. Predictors of post-operative mycetoma Recurrence using machine-learning algorithms: the mycetoma research center experience. *PLoS Negl Trop Dis.* 2016;10(10): e0005007.

17. Awad A, Alnaser A, Abd-Elmaged H, Abdallah R, Khougali HS. Eumycetoma Osteomyelitis Calcaneus in Adolescent; report of case and literature review. *BMC Infectious Diseases.* 2021 Dec;21(1):1-4.





### Hosted file

file 4.docx available at <https://authorea.com/users/497999/articles/578890-actinomycetoma-distal-radius-mimic-osteosarcoma-case-report-of-rare-presentation>

### Hosted file

file 5.docx available at <https://authorea.com/users/497999/articles/578890-actinomycetoma-distal-radius-mimic-osteosarcoma-case-report-of-rare-presentation>