

Extracorporeal photopheresis: is one ounce of blood enough? Cases report

Kumukova Irina¹, Elena Kurnikova¹, and Trakhtman Pavel¹

¹Rogachev Federal Scientific and Clinical Centre of Pediatric Hematology Oncology and Immunology

March 7, 2023

Abstract

Extracorporeal photopheresis (ECP) has proven effective in the treatment of several diseases, including acute and chronic graft-versus-host disease (GVHD) after allogeneic hematopoietic stem cell transplantation. In its standard version, ECP requires leukapheresis to obtain a fraction of mononuclear cells. The possibility of using leukapheresis is limited by the requirements for vascular access and the somatic status of the patient. We have developed a new ECP method that does not require leukapheresis. This paper presents a description of two clinical cases of severe refractory GVHD treated by micro-ECP.

Extracorporeal photopheresis: is one ounce of blood enough?

Cases report

Kumukova Irina¹, ORCID ID 0000-0002-9881-1041, irina_kumukova@mail.ru

Kurnikova Elena¹, ORCID ID 0000-0003-4767-5382, ekurnikova@yandex.ru

Trakhtman Pavel¹. ORCID ID 0000-0002-0231-1617, trakhtman@mail.ru

Rogachev Federal Scientific and Clinical Centre of Pediatric Hematology Oncology and Immunology: Moscow, Russia

Corresponding author: Kumukova Irina¹+7925038400, Rodnikovaya str. 30, ap.121, Moscow, Russia 119297

Conflict of interest declaration . Authors no conflict of interest

Word Count for

Abstract: 87

Main Text (excludes title page, abstract, Conflicts of Interest, Acknowledgments, References, Tables, Figures, and Legends): 1200

The number of Figures - 2

Short running title: Micro-ECP

Keywords: Extracorporeal photopheresis, photopheresis, graft-versus-host disease.

Abbreviations

| | |
|------|------------------------------|
| ECP | extracorporeal photopheresis |
| GVHD | graft-versus-host disease |

| | |
|-----|------------------------------|
| ECP | extracorporeal photopheresis |
| CSA | cyclosporine A |
| GI | gastrointestinal |

Ethics Statement

The legal representatives of the patients gave their consent to the experimental therapy and they were notified that photographic materials will be anonymized prior to review.

Abstract

Extracorporeal photopheresis (ECP) has proven effective in the treatment of several diseases, including acute and chronic graft-versus-host disease (GVHD) after allogeneic hematopoietic stem cell transplantation. In its standard version, ECP requires leukapheresis to obtain a fraction of mononuclear cells. The possibility of using leukapheresis is limited by the requirements for vascular access and the somatic status of the patient.

We have developed a new ECP method that does not require leukapheresis. This paper presents a description of two clinical cases of severe refractory GVHD treated by micro-ECP.

Background

Extracorporeal photopheresis (ECP) is a treatment with great but not fully realized potential. The ability to achieve immunoregulatory effects without immunosuppression is the main advantage of ECP. However, in the clinical practice the possibility of using ECP is limited, due to the need for leukapheresis. Therefore, for more than 20 years, attempts have been made to perform ECP without the use of leukapheresis, by obtaining a sufficient number of leukocytes for a therapeutic effect, namely the mononuclear fraction, from small doses of whole blood [1-3].

In the past we experienced extremely difficult clinical cases: severe refractory acute graft-versus-host disease (GVHD) and severity of the patients' illness. We have therefore developed a new method of therapy – micro-ECP, for compassionate use.

Results

Method description

We performed effusion of 20-30 ml of the patient's whole blood in a syringe (50ml) with 5ml of anticoagulant (ACD-A). The volume of effusion depended on the level of hematocrit. This was the most important limiting factor, as the maximum dilution was allowed up to 300ml as required by the ECP system manufacturer. The obtained whole blood was injected into a photopheresis bag (MacoPharma, France) adding 5 ml of 8-MOP (Metoxsalene S.A.L.F, Italy) and incubated in the dark at room temperature for 1 hour. Then sterile NaCl 0.9% solution was added into the bag to 300 ml. The resulting cell product was irradiated with ultraviolet light in the MacoGenic G2 (MacoPharma, France). After phototreatment, the cell product was reinfused to the patient.

Cases presentation

Patient 1 (Fig 1, a). A 15-year-old boy diagnosed with X-linked lymphoproliferative syndrome type 1 (deletion in exon 1 of the SH2D1A gene in the hemizygous state) was transplanted from a haploidentical donor (father) with TCR $\alpha\beta$ + / CD19+ depleted peripheral hematopoietic stem cells. In the early post-transplantation period (from Day +12) he experienced an "engraftment syndrome" – maculopapular rash on the trunk and palmar-plantar erythema equivalent to acute GVHD stage II, skin-2. The immunosuppression was initiated with methylprednisolone 2 mg/kg/day for 3 days, tapered to 1 mg/kg/day. Against the background of a decrease in the dose of methylprednisolone, the patient's condition worsened from Day +17: progression of the acute GVHD to stage III (GI-3, skin-3), and upper intestinal lesion with the development of severe nausea, vomiting, lack of appetite, severe abdominal pain syndrome requiring morphine. Patient suffered a

GI hemorrhagic syndrome (gastroscopy results). No pathogens were identified in the feces. The patient's condition was at risk of infectious complications due to presence of CMV viremia. On Day +21 the patient was diagnosed with acute GVHD stage 4 (GI-4, hemorrhagic colitis; skin - 4, generalized erythroderma). Further, the dose of corticosteroids was increased, and a multiple correction of the immunosuppressive therapy was also performed. Ruxolitinib, etanercept, cyclosporine A (CSA), and alemtuzumab were used at the recommended dosage, without GVHD improvement. After alemtuzumab (Day +24), there occurred a decrease in the number of T-cells to 40 cells/ μ l, followed by their rise to 92 cells on Day +28, and subsequent growth dynamics.

The multiple immunosuppressive therapy was ineffective, patient's condition progressively worsened, there were risks of severe infectious complications, and leukapheresis was impossible. We have therefore developed a modification of ECP without leukapheresis, as compassionate therapy. Since we were well aware that the number of targeted cells received is extremely small, the ECP schedule was set to 4 procedures per week.

On Day + 29 we started the micro-ECP therapy. For 5 consecutive weeks, the patient received 4 micro-ECP treatments per week as described before. On the second week of micro-ECP therapy GVHD progression stopped, and on the third week we could already see a clear regression. The skin manifestations did not worsen and turned into hyperpigmentation, hemorrhagic colitis completely disappeared, and the volume of stool decreased. On Day +56 (fourth week of micro-ECP treatment), the skin syndrome was represented by residual hyperpigmentation of the chest, abdomen, back, upper limbs; intestinal syndrome - thick stool once in 2-3 days. The immunosuppressive therapy and the frequency of micro-ECP procedures were gradually decreased to 1 in 4 weeks by 22 weeks. However, from the Day +320 a folliculitis-like rash appeared on the abdomen, chest and back (chronic GVHD?) - methylprednisolone dose was augmented and CSA was changed to ruxolitinib. The frequency of micro-ECP procedures was increased to 1 per week, followed by a gradual decrease to 1 at 4 weeks to 65 weeks.

The total duration of micro-ECP therapy was 69 weeks. The graft function is currently satisfactory. There are no signs of progression of chronic GVHD. Immunosuppressive therapy: ruxolitinib 5 mg x 3 times a day, prednisolone 2.5 mg x 2 times a day.

Patient 2 (Fig 1, b). A 2-year-old girl diagnosed with acute myeloid leukemia, M2, t(X;11)(q24;q23) KMT2A/SEPT6 gene after allogeneic bone marrow transplantation from a haploidentical donor (father). The early post-transplant period was complicated by mucositis grade 3, neutropenic enterocolitis. The first signs of acute GVHD appeared on Day +5 - skin lesions-2, Grade I. Treatment with methylprednisolone (1mg/kg) and etanercept was started. Despite the ongoing therapy, from Day +12 progression of acute GVHD with an increase skin lesions up to grade 3 and elevation of bilirubin (acute GVHD III) was noted. Immunosuppressive therapy was modified - a short course of high-dose methylprednisolone (5mg/kg) followed by a gradual reduction; ruxolitinib was added to therapy for 3 days with a single injection of tocilizumab (162mg). Against the background of the therapy, GVHD progressed to generalized erythroderma with the formation of several small bullae (Grade IV).

The patient also suffered multiple infectious complications: CMV-viremia (Day +18), treated with ganciclovir 10 mg/kg followed by switching to foscarnet (for 2 weeks) due to a decrease in neutrophils; COVID-19 associated pneumonia from Day +24, treated with remdesivir. Taking into account the need to control GVHD and to reduce immunosuppressive therapy (viral infections, high-risk AML), a course of extracorporeal photopheresis was indicated. We decided to start micro-ECP course from Day +27. The response to micro-ECP was obtained in the first week as a lack of progression of GVHD, in the second week as regression of skin and liver GVHD. At 4 weeks of micro-ECP, there were no signs of active GVHD. Subsequently, the immunosuppressive therapy was reduced, and the frequency of micro-ECP procedures was gradually reduced. There was no recurrence of GVHD, and after 27 weeks of micro-ECP treatment the patient was discharged from hospital without immunosuppressive therapy, and with complete healing of GVHD.

Discussion

Our method has been applied as "compassionate use" in difficult clinical cases. To be honest, we did not

expect to see a quick and final (permanent?) result. At first, we intended to administer the micro-ECP until the patient’s condition improved, with the subsequent transition to standard ECP. However, this was not required. The amazing response we were able to achieve with a minimum number of cells, inspired us to continue the therapy in the form of micro-ECP, which was justified. Both patients completely recovered from GVHD.

The micro-ECP method needs further research. It is necessary to understand for whom it can be effective, for whom it will not help, and what variables influence the effectiveness of therapy. ECP, developed more than 30 years ago, still excites our minds and provides the ground for the extension of clinical investigation

Figure 1. Patients treatment history.

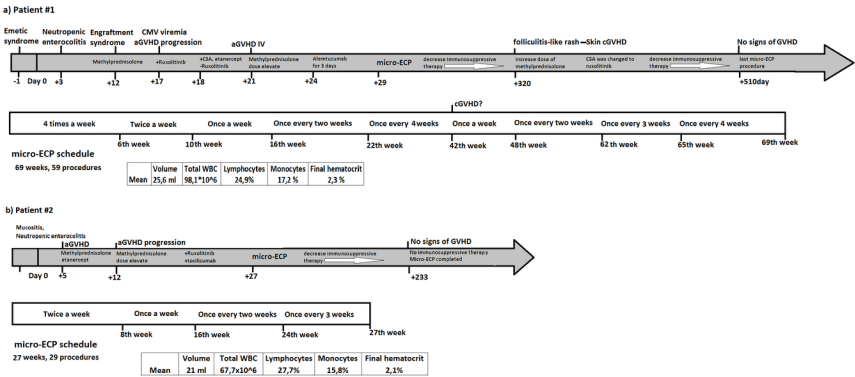


Figure 2. Response to micro-ECP.

| | Initial state | After 2 weeks micro-ECP therapy | After 4 weeks micro-ECP therapy |
|---------|---------------|---------------------------------|---------------------------------|
| Patient | | | |
| 1 | | | |
| Patient | | | |
| 2 | | | |

References

van Iperen HP, Beijersbergen van Henegouwen GM. Clinical and mechanistic aspects of photopheresis. J Photochem Photobiol B 1997; 39(2):99-109. doi: 10.1016/s1011-1344(96)07432-5. PMID: 9225456.

T. Schreiner, A. Gaczkowski, K. Scharffetter-Kochanek, H. Borberg. Small-scale extracorporeal photopheresis for the treatment of cutaneous T-cell lymphoma: A report of 3 cases. Transfusion and Apheresis Science 2005; 32:2:197-203

Hackstein H, Misterek J, Nockher A, Reiter A, Bein G, Woessmann W. Mini buffy coat photopheresis for children and critically ill patients with extracorporeal photopheresis contraindications. Transfusion 2009; 49(11):2366-73. doi: 10.1111/j.1537-2995.2009.02289.x. PMID: 19903292.