

# Rare pyoderma gangrenosum correlated with systemic lupus erythematosus: A case report

omid pourbagherian<sup>1</sup>, kamran javidi<sup>2</sup>, mohammad taghizadieh<sup>1</sup>, and Mehdi Jafarpour<sup>1</sup>

<sup>1</sup>Tabriz University of Medical Sciences

<sup>2</sup>Tabriz Medical University

May 13, 2023

## **Rare pyoderma gangrenosum correlated with systemic lupus erythematosus: A case report**

Omid pourbagherian<sup>1</sup>, Kamran Javidi<sup>1</sup>, Mohammad Taghizadieh<sup>3</sup>, Mehdi Jafarpour<sup>2\*</sup>

<sup>1</sup> Immunology Research Center, Tabriz University of Medical Sciences, Tabriz, Iran

<sup>2</sup>Connective Tissue Diseases Research Center, Tabriz University of Medical Sciences, Tabriz, Iran

<sup>3</sup>Department of Pathology, Tabriz University of Medical Sciences, Tabriz, Iran.

Drafting of the manuscript: Mehdi Jafarpour, Omid pourbagherian

Data Collection: Kamran Javidi, Mohammad Taghizadieh, Mehdi Jafarpour

Critical revision of the manuscript for important intellectual content: Mehdi Jafarpour, Omid pourbagherian

Case supervision: Mehdi Jafarpour

Corresponding author: Mehdi Jafarpour

Address: Connective Tissue Diseases Research Center, Flat 1, Imam Reza Hospital, Tabriz, Iran

Phone number: 0098 41 33332704

Fax: 0098 41 35413520

Mobile: 09148651269

Reference count: 10

Figure/table count: 2/1

Funding: none.

Conflict of interest: none

Written informed permission from the patient to publish the facts and photographs was granted.

Manuscript word count:999

## **Keywords**

Pyoderma gangrenosum, Systemic lupus erythematosus, inflammatory skin disease

## **Introduction**

Pyoderma gangrenosum (PG) is an infrequent kind of inflammatory skin disease that may lead to the development of swiftly expanding and distressing skin ulcers(1). The initial documentation of PG was conducted by Dr. Louis Brocq in 1916. However, it was not until the 1930s that Dr. Brunsting characterized a series of patients with identical clinical symptoms(2). The etiology of PG remains unclear; however, it is hypothesized to be an autoimmune condition characterized by the immune system's attacks on healthy tissue, resulting in the development of ulcerations.PG impact individuals of all gender, race, or ages, albeit with a higher incidence rate among adults and a greater prevalence among the female (3).

PG is correlated with fundamental medical conditions, including inflammatory bowel disease (IBD), rheumatoid arthritis, lupus, and specific blood disorders. It is plausible for it to manifest consequent to pharmaceutical administration or subsequent to surgical intervention or physical injury(4).The concurrent development of PG with systemic lupus erythematosus (SLE) is an infrequent phenomenon, with only a limited number of cases having been documented.

PG can be classified into multiple groups, which include:

- 1.Classic PG: The prevalent manifestation which is distinguished by the prompt emergence of distressing ulcers featuring elevated, purple borders
- 2.Bullous PG: This form can be identified by the emergence of vesicles containing fluid that rapidly disintegrates, forming ulcers.
- 3.Pustular PG: This form can be recognized by the appearance of multiple small pustules that amalgamate to create distressing ulcers.
- 4.Vegetative PG: This class stands out by the emergence of skin lesions resembling cauliflower growths that pose a challenge for effective management.
- 5.Postoperative PG: This type manifests after surgical procedures and is believed to be associated with skin trauma or injury.
- 6.Systemic PG: The last form is linked with systemic illnesses, such as rheumatoid arthritis and rarely SLE(5).

The clinical manifestations of PG include the emergence of one or multiple painful, swiftly advancing ulcers or lesions with uneven margins and a necrotic core. It is noteworthy that the clinical manifestation of PG has the potential to resemble other medical conditions, including infections, malignancies, or autoimmune disorders. Therefore, an accurate diagnosis necessitates a comprehensive medical assessment(3).

PG is a condition that can be effectively managed through various treatment modalities which may encompass corticosteroids, immunosuppressive medications, antibiotics, and surgical intervention. Timely medical intervention is crucial in cases of PG, as prompt treatment can mitigate the risk of complications and enhance prognosis.

## CASE REPORT

The subject of this case study is a female patient who is 55 years old and has been diagnosed with lupus for 20 years. Additionally, she has been diagnosed with lupus nephritis for 14 years and has been receiving intermittent treatment with immunosuppressive and corticosteroid medications such as hydroxychloroquine, cyclosporine, mycophenolate mofetil, and prednisolone in varying dosages. The aforementioned patient had severe skin lesions in the form of two painful papules in the anterior and lateral areas of the leg. These papules progressively became larger and transformed into an ulcerated lesion with 5×5 cm dimensions, and the center of the lesions was found to be necrotic (Figure 1). Concomitant with the disease, the individual exhibited a malar rash, small joint arthritis, and renal involvement.

The individual exhibiting these clinical manifestations was admitted to the Rheumatology Department at Imam Reza Hospital in Tabriz, where, based on following consultation with the medical team, the patient was scheduled to undergo a skin biopsy as a means to pursue further investigation. The dermatology

team conducted a skin biopsy (Figure 2). The biopsy's pathology results showed skin tissue with compact hyperkeratosis, acanthosis, associated with superficial dermal fibrosis and intradermal neutrophilic abscess formation, and leukocytoclastic vasculitis which was compatible with PG, in the early stage.

Initial results of laboratory blood tests revealed elevated levels of erythrocyte sedimentation rate (ESR) and C-reactive protein (CRP). Also, levels of anti-dsDNA antibody increased. The levels of other blood test parameters are shown in Table 1.

The patient was treated with pulse therapy of methylprednisolone (1g) for 3 consecutive days and an injection of Cyclophosphamide (750mg). Subsequently, prednisolone dosage began tapering

gradually (40 mg) and Cyclophosphamide was injected monthly.

## DISCUSSION

PG is an uncommon kind of inflammatory skin disease that is not caused by an infection and is characterized by painful necrotic ulcers that often appear on the legs(6). It is believed that PG is an autoimmune disease; however, the exact cause of the disease is not completely known.

Although PG is frequently linked with systemic conditions such as inflammatory bowel disease, rheumatoid arthritis, and hematologic malignancies, the incidence of PG as a prior symptom of SLE is very uncommon and has only been described in a few individuals to this point(7).

The identification of PG is established through the process of excluding other potential sources of cutaneous ulcerations that present with similar characteristics, such as infections, cancers, vasculitides, venous insufficiencies, and trauma(8).

To date, in the majority of cases that have been documented, before the manifestation of PG symptoms, a diagnosis of SLE was made. H. B. Kwon et al. delineated the clinical manifestation of PG in a female patient aged 35 years, who exhibited the characteristic symptom of painful ulcers on her lower extremities as our case. The subsequent assessment indicated that the patient also presented with SLE, posited as the fundamental etiology of her dermatological manifestation. They deliberate on the plausible mechanisms that connect the two aforementioned conditions and underscore the significance of prompt identification and intervention(9).

In another case study, S. N. Jha et al. demonstrated a female patient, aged 30 years, diagnosed with SLE, presented with PG affecting her lower limbs. The authors delve into the plausible immunological mechanisms that underlie this correlation and emphasize the significance of interdisciplinary administration(10).

## Conclusion

In this case study article, we demonstrated a rare case of PG related to SLE. The results of our study provide evidence for a potential correlation between active SLE and PG, although the underlying mechanism remains unknown. Considering the treatment which our team performed with a complete recovery, we suggested this first-line treatment strategy.

## Acknowledgments

The authors express their gratitude for the valuable contribution made by the patient in providing biopsy and blood donation.

The authors appreciate support provided by Imam Reza Hospital, Tabriz, Iran.

## Author contributions

All authors approved the final manuscript.

## Funding

Not applicable

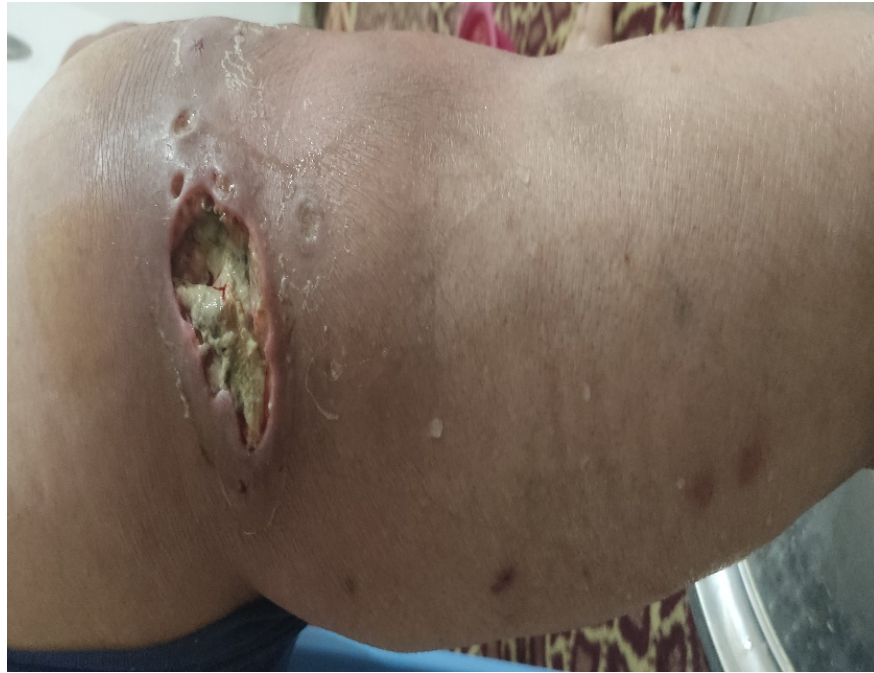### **Declarations**

Ethics approval and consent to participate.

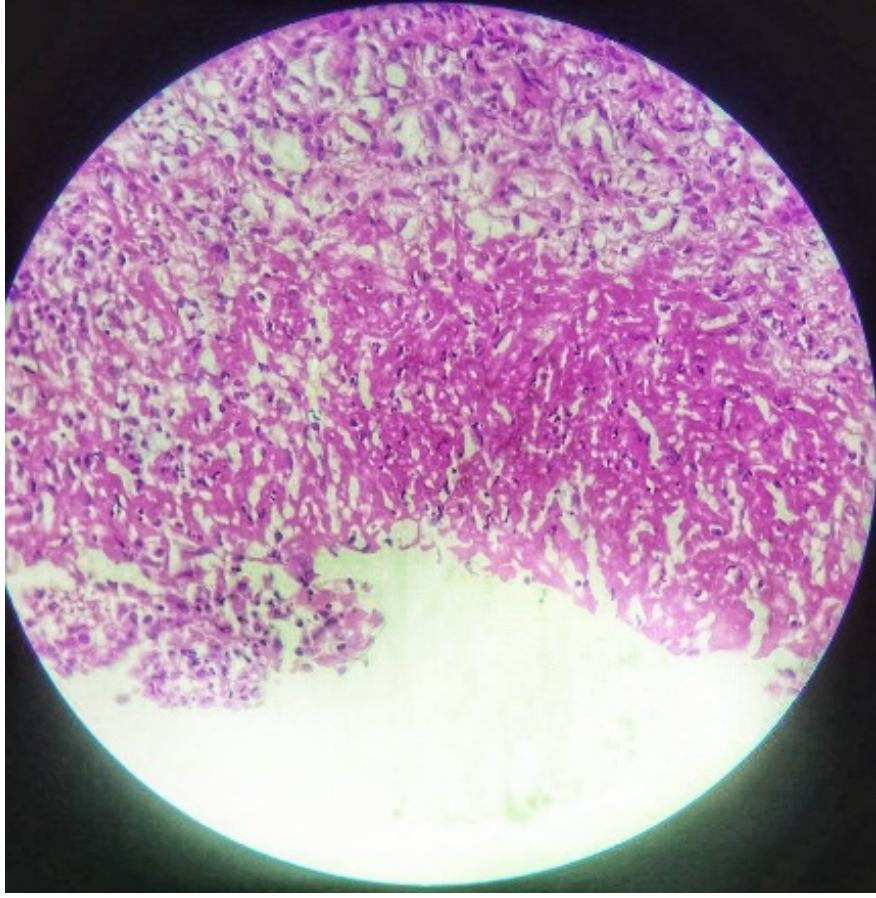
This study has been performed according to the Declaration of Helsinki.

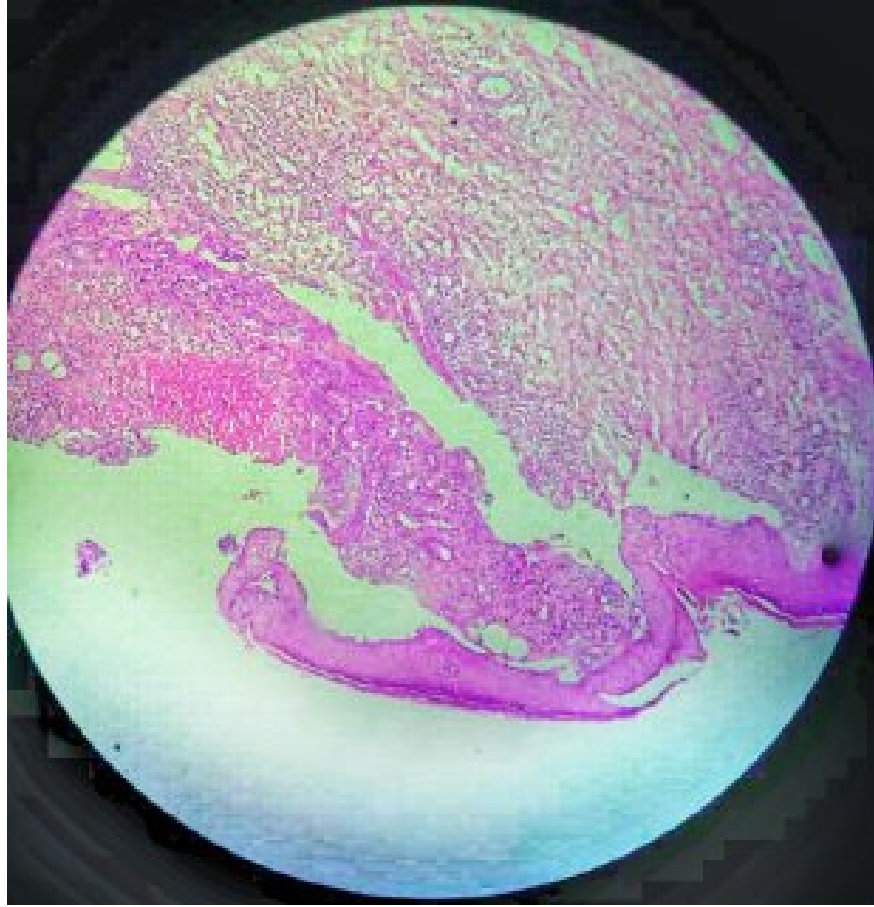
### **Competing interests**

The authors declare that they have no competing interests.



**Figure 1** . A mucopurulen painful and ulcerated lesion of right sided foot with irregular borders compatible with pyoderma gangrenosum.





**Figure 2.** A Microscopic view (histologic) of bar-shaped skin with subcutaneous tissue (H&E,  $\times 10$ ) showed hyperkeratosis, and acanthosis, associated with superficial dermal fibrosis and intradermal neutrophilic abscess formation.

**Table 1.**

Blood test results of the patients at initial medical examination

Laboratory tests (unit)	Laboratory values	Normal range
WBC ( $\times 1000/\mu\text{l}$ )	8.1	4.0-11.0
Hb (g/dl)	8	12-18
Plt ( $\times 1000/\mu\text{l}$ )	151	130-440
ESR 1nd hr (mm/hr)	80/20	Female: < 50 Years up to 30
CRP (mg/L)	86/6	Up to 6
ANA (IU/mL)	Positive	< 30.0
Anti dsDNA (IU/mL)	100/20	< 10
C3 mg/dL	70/90	75 to 175
C4 mg/dL	Normal	16 to 48
Aps Ab U/L	Negative	8 to 33
Creatinine (mg/dl)	2	16-120
Urea (mg/dl)	108	12.8-43
LFT	Normal	-

Laboratory tests (unit)	Laboratory values	Normal range
24 hr urine protein (mg/m <sup>2</sup> / day)	1200	<100

## References

1. Powell FC, Collins S. Pyoderma gangrenosum. *Clinics in dermatology*. 2000;18(3):283-93.
2. Ye MJ, Ye JM. Pyoderma gangrenosum: a review of clinical features and outcomes of 23 cases requiring inpatient management. *Dermatology research and practice*. 2014;2014:461467.
3. Skopis M, Bag-Ozbek A. Pyoderma gangrenosum: a review of updates in diagnosis, pathophysiology and management. *J*. 2021;4(3):367-75.
4. Callen JP. Pyoderma gangrenosum and related disorders. *Medical Clinics of North America*. 1989;73(5):1247-61.
5. Bhat RM. Pyoderma gangrenosum: An update. *Indian dermatology online journal*. 2012;3(1):7.
6. Braswell SF, Kostopoulos TC, Ortega-Loayza AG. Pathophysiology of pyoderma gangrenosum (PG): an updated review. *Journal of the American Academy of Dermatology*. 2015;73(4):691-8.
7. Brooklyn T, Dunnill G, Probert C. Diagnosis and treatment of pyoderma gangrenosum. *Bmj*. 2006;333(7560):181-4.
8. Kozono K, Nakahara T, Kikuchi S, Itoh E, Kido-Nakahara M, Furue M. Pyoderma gangrenosum with increased levels of serum cytokines. *The Journal of Dermatology*. 2015;42(12):1186-8.
9. Kwon HI, Paek JO, Kim JE, Ro YS, Ko JY. Pyoderma gangrenosum in a patient with hereditary spherocytosis. *The International Journal of Lower Extremity Wounds*. 2016;15(1):92-5.
10. Jena A, Sachan A, Singh AK, Sharma V. Multifocal pyoderma Gangrenosum at presentation in a patient with acute severe ulcerative colitis. *Inflammatory Bowel Diseases*. 2022;28(6):e84-e5.

## Hosted file

figure.docx available at <https://authorea.com/users/617984/articles/643163-rare-pyoderma-gangrenosum-correlated-with-systemic-lupus-erythematosus-a-case-report>

## Hosted file

table.docx available at <https://authorea.com/users/617984/articles/643163-rare-pyoderma-gangrenosum-correlated-with-systemic-lupus-erythematosus-a-case-report>