

Granzyme B is elevated in esophageal biopsies in Pediatric Eosinophili

Helena Thulin¹, Jesper Säfholm², Joachim Lundahl¹, Viktor Jovic³, Mikael Adner², and Caroline Nilsson¹

¹Karolinska Institutet Institutionen for klinisk forskning och utbildning Sodertjukhuset

²Karolinska Institutet Institutet for miljömedicin

³Karolinska Universitetslaboratoriet Klinisk patologi/cytologi avdelningen

December 15, 2023


Abstract

BACKGROUND: Eosinophilic esophagitis (EoE) is an immune-mediated antigen-triggered inflammatory disease of the esophagus. Our aim was to investigate inflammatory responses by a n

ORIGINAL ARTICLE

Gastroenterology: Eosinophilic Gastrointestinal Disorders

Granzyme B is elevated in esophageal biopsies from children with eosinophilic esophagitis

Helena Thulin^{1,2}  | Jesper Säfholm³ | Joachim Lundahl^{1,4} | Viktor Jovic⁵ | Mikael Adner³ | Caroline Nilsson^{1,6}

¹Department of Clinical Science and Education, Karolinska Institutet, Stockholm, Sweden

²Astrid Lindgren Children's Hospital, Division of Pediatric Gastroenterology, Hepatology and Nutrition, Karolinska University Hospital, Stockholm, Sweden

³Experimental Asthma and Allergy Research, Department of Environmental Medicine, Karolinska Institutet, Stockholm, Sweden

⁴Department of Medical Diagnostics, Karolinska University Hospital, Stockholm, Sweden

⁵Department of Clinical Pathology and Cytology, Karolinska University Laboratory, Stockholm, Sweden

⁶Sachs Children and Youth Hospital, Department of Pediatric Allergy and Pulmonology, South Hospital, Stockholm, Sweden

Correspondence

Helena Thulin, Astrid Lindgren Children's Hospital, Division of Pediatric Gastroenterology, Hepatology and Nutrition, Karolinska University Hospital, Stockholm 17176, Sweden.
Email: helena.thulin@regionstockholm.se

Funding information

Mjölkdroppen; The Samariten Foundation

Abstract

Objectives: Eosinophilic esophagitis (EoE) is an immune-mediated antigen-triggered inflammatory disease of the esophagus. Our aim was to investigate inflammatory responses by an ex vivo biopsy provocation-based method, stimulating biopsies with milk, wheat, and egg extracts.

Methods: An experimental study was conducted on esophageal biopsies from children who underwent esophagogastroduodenoscopy. Supernatants were collected before and after stimulation of the biopsies with food extracts and analyzed for 45 different inflammatory markers. Biopsies were also stained for histological analyzes.

Results: Study subjects included 13 controls, 9 active EoE, and 4 EoE in remission, median age 12 years. Of the 45 markers analyzed, three had significant differences between controls and patients with active EoE, Granzyme B, (GzmB), IL-1ra, and CXCL8 ($p < .05$). Levels of GzmB were higher, and levels of IL-1ra were lower in patients with active EoE compared with controls and EoE in remission both at baseline and after food extract stimulation. CXCL8 increased in active EoE compared with controls only after stimulation. The number of histologically detected GzmB-positive cells were significantly higher in patients with active EoE in contrast to control and EoE remission ($p < .05$).

Conclusions: The levels of the barrier-damaging protease GzmB were higher in the supernatant both before and after stimulation with food extract ex vivo in patients with active EoE. GzmB was also observed histologically in biopsies from patients with active EoE. The presence of elevated serine protease GzmB in esophageal mucosa of children with active EoE suggests a role in the pathogenesis of this disorder.

KEYWORDS

CXCL8 (IL-8), food extracts, immunological markers, impaired barrier function, serine protease

1 | INTRODUCTION

Eosinophilic esophagitis (EoE) is a non-IgE immune-mediated food antigen-driven disease strictly located to the esophagus that can cause dysphagia in connection

with a meal and reduce both growth and quality of life.¹ In the youngest children, vomiting or feeding difficulties are common symptoms, while adolescents can experience food obstruction and reflux.² EoE is more common among patients with eczema, asthma, and/

Abbreviations: DMEM-F12, Dulbecco's Modified Eagle Medium with F-12 nutrient addition; EGD, esophagogastroduodenoscopy; EoE, eosinophilic esophagitis; eos, eosinophils; GzmB, Granzyme B; hpf, high power field.

© 2023 European Society for Pediatric Gastroenterology, Hepatology, and Nutrition and North American Society for Pediatric Gastroenterology, Hepatology, and Nutrition.

or IgE-mediated food allergy.² The disease could possibly be underdiagnosed due to the absence of biomarkers and sometimes unclear symptoms.

Although a complete understanding of EoE pathogenesis is lacking, a T helper type 2 (Th2) cytokine-mediated inflammation is suggested.^{3,4} Multiple mechanisms have been proposed such as allergens, microorganisms, genes, gastroesophageal reflux, and impaired barrier function.⁵ Epithelial barrier dysfunction seems to play a central role in the pathophysiology of EoE,⁶ and a dysfunctional barrier could facilitate passage of molecules, but the mechanisms remains unclear. Due to the chronic nature of the disease, treatment is recommended for active symptomatic EoE.^{7,8}

Our primary aim was to measure the inflammatory markers generated by esophageal biopsies before and after stimulation by food extracts solutions *ex vivo*. This was performed using a tissue culturing technique where biopsies were incubated and exposed to food extracts from milk, wheat, and egg. The secondary aims were to investigate the corresponding responses in blood and saliva from the patients as well as performing histological analysis of the biopsies.

2 | METHODS

2.1 | Study participants

Children and adolescents 0–18 years who underwent esophagogastroduodenoscopy (EGD) at Sachs Children's and Youth Hospital between September 2019 and January 2020 due to suspicion of, or follow-up of known EoE, or other upper gastroenterological issues, were invited to participate in the study. EGDs were performed during anesthesia. From each patient, two biopsies were taken from distal and proximal parts of the esophagus, and in some patients two additional from the middle esophagus, that were all sent for regular pathological-anatomical diagnosis (PAD). For biopsy stimulation, two additional biopsies from the middle esophagus were taken. Blood and saliva were collected from all patients at the time of EGD.

2.2 | Ex vivo biopsy stimulation

The study biopsies were immediately placed in a tube with cold (5°C) Krebs-Ringer PSS buffer solution and then placed in 24-well culture plates containing 500 μ L Dulbecco's Modified Eagle Medium with F-12 nutrient addition (DMEM-F12; Gibco,) overnight. The following day, the culture medium was carefully removed with a pipette, and fresh DMEM-F12 was added. After 60 min, the medium was collected and stored directly in -80°C , as a measurement of basal release over 60 min. This

What is New?

- The serine protease Granzyme B (GzmB) was found at higher levels in the supernatant in patients with active Eosinophilic Esophagitis (EoE) and observed histologically in biopsies from patients with active EoE.
- No association has been previously described between EoE and GzmB.
- The finding of presence of the barrier damaging GzmB in active EoE suggests a role in the pathogenesis of this disorder.

What is Known?

- The epithelial protective barrier is important in the esophagus and a dysfunctional barrier can facilitate passage of molecules.
- Serine proteases can lead to barrier damage.

was followed by a protocol exposing the biopsies in DMEM-F12 to extracts for wheat or egg yolk (5 μ L, respectively) for 60 min each, followed by collection of the supernatant. Then, new DMEM-F12 medium was added, individually to egg white and cow's milk extracts (5 μ L respectively) for an additional 60 min before collection of the supernatant. The collected medium was frozen and stored in -80°C until analyses of immunological markers.

2.3 | Investigation of immunological markers

To investigate immunological markers, LKTM014 Human XL Cytokine Magnetic Luminex Performance Assay 45-plex Fixed Panel (45-Plex), (Bio-Techne Ltd) was used. The procedure for the determination of immunological markers in our cell culture supernatants was performed according to manufacturer protocol. Values were normalized to the weight of the segment and mean values for immunological markers combining different food extracts are reported in pg/mg wet weight of biopsy.

2.4 | Food extracts preparation

The food extracts solutions were prepared from lyophilized raw material (500 mg each) from Allergon AB (ThermoFisher Scientific) dissolved in 50 mL phosphate-buffered saline. The mean protein concentration was for wheat 0.25 mg/mL, egg yolk 3.5 mg/mL, egg white 15 mg/mL, and cow's milk 3.5 mg/mL which was diluted 1:100 when added to DMEM-12.

2.5 | Histological analysis

Formalin-fixed paraffin-embedded 3 μ m thick sections were stained with hematoxylin–eosin for assessment of eosinophilic granulocytes in epithelium. Occurrence of Granzyme B was investigated using mouse anti-Granzyme B, clone GrB-7 antibody (Monosan). Staining was performed on Roche Diagnostics. Counting of eosinophils and Granzyme B positive cells were expressed as a peak count per one high power field (hpf).

2.6 | Blood and saliva analysis

Venous blood was collected in vacutainer tubes (Becton, Dickinson ref nr 368498, 369623, and 367862). For saliva, patients held a synthetic swab in their mouth until it was wet with saliva, which took about a minute. After that, the swab was placed in a saliva tube (Salivette, Sarstedt, ref nr. 1534500), centrifuged, aliquoted, and frozen in -80°C pending analyses.

IgE-antibody (IgE-ab) levels for milk, egg, wheat, birch, and timothy were analyzed in serum with ImmunoCap[®] (ThermoFisher Scientific) and levels $>0.1 \text{ kAU/L}$ were considered as a positive result. Granzyme B (GzmB) was analyzed in serum and saliva with Quantakine HS ELISA, Human Granzyme B Immunoassay, Catalog nr HSGZBO (Bio-Techne Ltd), according to the manufacturer's protocol.

2.7 | Ethical approval

The study was approved by the Regional Ethical Review Board of Stockholm (D-nr 2017/744-31, 2018/253-32, 2018/1931-3, 2019/05376 and 2022-03084-02). Informed written consent was obtained from patients. For children less than 15 years of age, both guardians approved before inclusion in the study.

2.8 | Statistical analysis

Descriptive data are presented as percentage and median values with range. Kruskal–Walli's test and intergroup differences assessed by Dunn's multiple comparisons test was used. When two groups comparison, Mann–Whitney was used. Outliers were detected and removed using ROUT method (with Q set to 1%). The correlations were studied using Spearman's correlation coefficient. For categorical values, Fisher's exact test was used. A p value of less than 0.05 was considered statistically significant. Statistics software STATA/SE15 Intercooled and GraphPad Prism (GraphPad Prism version 9.0.0 for Windows, GraphPad Software) were used.

3 | RESULTS

3.1 | Patient demographics and clinical information

A total of 26 patients were included in the study. The median age was 12.2 years (range 4.3–17.9). The patients were divided into three groups following pathological diagnosis:

1. Controls: $N=13$, patients without eosinophils in esophageal biopsies.
2. Active EoE patients: $N=9$, diagnosed by standard criteria⁹ ≥ 15 eosinophils/hpf on at least one esophageal biopsy and accompanying esophageal symptoms.
3. EoE patients in remission: $N=4$, patients with a history of EoE whose current biopsies had less than 15 eosinophils/hpf and the previous symptoms were resolved.

There were more girls in the control group (85%) compared with those with EoE (15%) ($p < .05$). Asthma was more commonly diagnosed in patients with EoE (46%) compared with controls (12.5%) ($p < .05$). Participants with active EoE had higher levels of peripheral blood eosinophils and endoscopic findings compared with the other groups ($p < .05$). Serum IgE-ab levels for milk, egg, wheat, birch, and timothy, did not differ between the groups.

3.2 | Immunological markers at the basal release from the biopsies

The levels of the 45 immunological markers, analyzed from the supernatant at baseline from 53 biopsies were undetectable for IFN- γ , IL-4, IL-5, IL-7, IL-12p70, IL-13, IL-17a, IL-33, CCL4, PDGF-AB/BB, CCL5, TNF- α , TRAIL, CCL11, IL-2, CXCL10, TGF- α , FLT-3L and CSF2. For FGF BASIC, CXCL2, IL-17e, CD154, CCL19, IL-3, IL-6, CCL2, CSIF, INF- α , CSF3, CX3CL1, EGF, IL-1b, IL-15, and B7-H1 detectable levels were found in single biopsies. For GzmB, IL-1ra, CXCL8, CCL3, PDGF-AA, VEGF, IL-1a, CCL20, IFN- γ and CXCL1, detectable levels were found in at least 10% of biopsies. The markers that had detectable levels in most biopsies, and that were represented in the different patient groups following post hoc analyzes identifying outliers, were GzmB, CXCL8, and IL-1ra.

At baseline, before stimulation with food extracts, a higher level for GzmB (Figure 1A) was detected in the active EoE group compared with both the control group and EoE in remission, ($p < .05$). The levels of CXCL8 were significantly higher in the controls and the active EoE group compared with the EoE in remission ($p < .05$) (Figure 1B). For IL-1ra a significantly lower

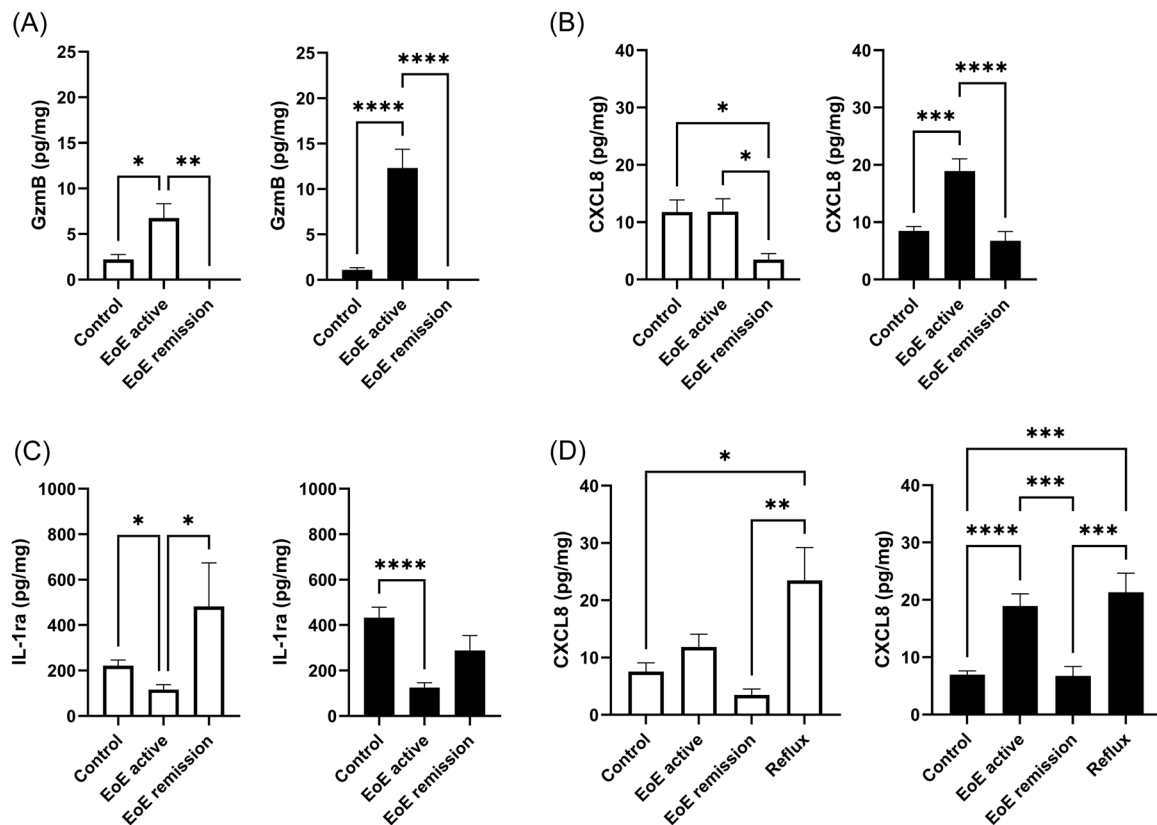


FIGURE 1 (A–D) Levels of Immunological markers at baseline and after stimulation with food extracts. The immunological markers with significant differences between groups are shown. Kruskal–Wallis's test followed by Dunn's multiple comparisons test was used. (A) GzmB at baseline (white) and after stimulation (black). (B) CXCL8 (IL-8) at baseline (white) and after stimulation (black). (C) IL-1ra at baseline (white) and after stimulation (black). (D) CXCL8 (IL-8) at baseline (white) and after stimulation (black), reflux separately.

value was detected in the active EoE group compared with both the control group and EoE in remission, ($p < .05$) (Figure 1C).

3.3 | In children with active EoE, levels of Granzyme B and CXCL8 increased and IL-1ra decreased after food extract stimulation

After ex vivo stimulation with food extract GzmB increased and there were statistically higher levels in the active EoE group compared with both control and EoE in remission ($p < .05$) (Figure 1A). In the active EoE group, the release of GzmB almost doubled compared with baseline, from 6.8 ± 1.6 to 12.3 ± 2.1 pg/mg, whereas in the control group it was halved, from 2.2 ± 0.5 to 1.1 ± 0.2 pg/mg.

The levels of CXCL8 also increased in the active EoE group after food extract stimulation and showed statistically higher levels compared with both controls and EoE in remission, ($p < .05$) (Figure 1B). The levels of IL-1ra were significantly lower in the active EoE group compared with controls ($p < .05$) (Figure 1C), as also observed at baseline.

Five of the 13 patients in the control group were diagnosed with reflux esophagitis by standard criteria.^{10,11} Thus, the results of the control group (controls without reflux, $n = 8$) were compared with the results of the reflux group ($n = 5$). However, no significant difference between reflux patients and the remaining control group was seen at baseline or stimulation for GzmB or IL-1ra, however, a difference between the reflux patients and the remaining control group for CXCL8 was found. We, therefore, performed an additional analysis with reflux patients as a separate group for CXCL8 (Figure 1D) revealing that at baseline the levels of CXCL8 were significantly higher in the reflux group compared with the remaining controls and EoE in remission ($p < .05$). In addition, after stimulation the levels of CXCL8 were increased in the active EoE group and continued at high levels in the reflux group. Active EoE showed statistically higher levels compared with both controls and EoE in remission, but not compared with the reflux group ($p < .05$). (Figure 1D).

Attempts were also made to evaluate values for the individual food extracts analyzed separately, however, this subgroup analysis showed no differences to any specific exposure when comparing between different patient groups (data not shown).

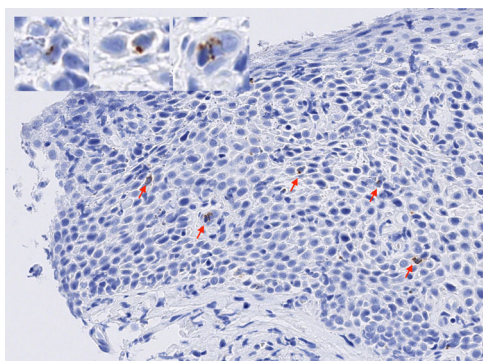


FIGURE 2 Histologic sections from an average patient with active eosinophilic esophagitis in GzmB staining depicts an increased number of mononuclear cells with granular cytoplasmic positivity (red arrows and inserts).

3.4 | Increased numbers of Granzyme B-positive cells were shown in biopsies from patients with active EoE

From all patients ($n=26$) there were paraffin-embedded biopsies to cut for staining with GzmB. From both EoE groups (active and remission) we were able to stain one biopsy from the proximal and one from the distal esophagus. There was no statistical difference in the number of GzmB-positive cells with respect to localization. Figure 2 displays biopsy histology from a typical patient with active EoE, illustrating the increased number of mononuclear cells with granular cytoplasmic positivity to GzmB in the squamous epithelium and unevenly distributed granules throughout the epithelium. Patients with active EoE showed an increased number of GzmB-positive cells in contrast to both control (reflux esophagitis included) ($p < .05$) and EoE in remission ($p < .05$) (Figure 3). The number of GzmB-positive cells correlated positively with the number of GzmB granules ($r = .79$, $p < .05$), however, there was no significant correlation between the number of eosinophilic cells/hpf and the number of GzmB-positive cells/hpf.

3.5 | Levels of Granzyme B in serum and saliva

The levels of GzmB were analyzed in serum and saliva in all study participants. All patients had measurable levels of GzmB in serum (mean level 31.7 ± 1.8 pg/mL). Although the mean GzmB level was higher in the active EoE group (35.4 ± 1.3 pg/mL) compared with the controls (28.4 ± 7.0 pg/mL), the difference was not significant.

In saliva, GzmB was present in measurable levels in 23/26 patients (mean level 13.7 ± 3.0 pg/mL). No difference could be detected between the groups.

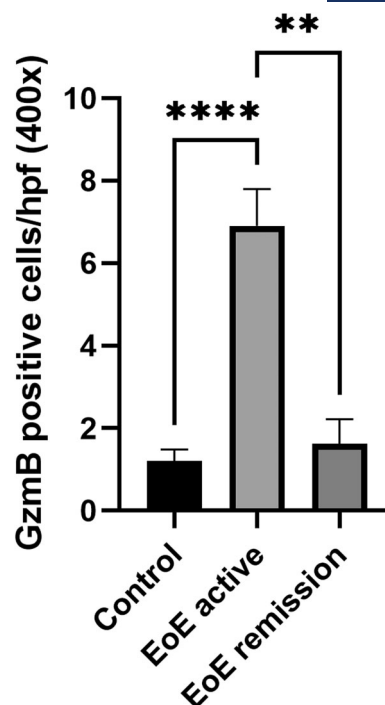


FIGURE 3 Granzyme B positive cells in biopsies of patients with active EoE are more numerous than in controls (reflux esophagitis included) or EoE in remission. Kruskal–Wallis's test followed by Dunn's multiple comparisons test was used. EoE, eosinophilic esophagitis. ** $p = .03$, **** $p < .0001$.

4 | DISCUSSION

EoE is a disease with not fully understood pathophysiology in part due to the unrecognized triggers of the local inflammatory cascade in the esophagus. We constructed a novel method by incubating esophageal tissue before and after exposure to wheat, egg, and cow's milk. Inflammatory cytokines were then measured in the supernatants obtained from the incubations. Using this method, we found that supernatants from children with active EoE, had augmented levels of GzmB at baseline and that these levels increased further after stimulation of biopsies. The higher GzmB levels in the active EoE group were accompanied by a higher number of GzmB-containing cells visually observed in the esophageal biopsies. This was not observed in children with EoE in remission, in patients with reflux esophagitis, or in the control group. Thus, our data presents the first described connection between EoE and GzmB. Compared with EoE in remission and with the controls, the inflammatory chemokine CXCL8 was increased in both EoE active patients and in patients diagnosed with reflux esophagitis after food extract stimulation. In contrast, levels of the inflammatory inhibitor IL-1ra were reduced in the active EoE group compared with the EoE remission group and controls.

GzmB is produced and secreted by immune cells, like T and B cell subpopulations, monocyte/macrophages, mast cells, and basophils, and by nonimmune

cells and tumor cells.¹² A unique accumulation of GzmB-positive cells is found in atopic dermatitis but not in healthy skin.¹³ It is known that part of the pathogenesis of EoE is barrier damage of the esophageal epithelium and GzmB is a serine protease that can lead to barrier damage. In previous studies, GzmB was linked to both asthma and eczema,^{13,14} which constitute risk factors for the development of EoE.² High serine protease expression in EoE was already described¹⁵ but the exact serine protease has not to our knowledge been specified. We speculate that GzmB may contribute to barrier damage in the esophagus, analogous to barrier damage in atopic dermatitis.¹³ With deterioration of the barrier in the esophagus, dietary and aeroallergens might penetrate the epithelium more easily and promote onset of EoE.

Several risk genes with known functions are described in EoE but also genes with unknown functions that may contribute to the mechanism of EoE. The production of GzmB seems to have its loci on 14q12¹⁶ which previously has been described as a risk factor in EoE, with unknown function.¹⁷ This is consistent with our data. We speculate that patients with a genetic modification of GzmB may develop a damaged barrier that allows antigens to be incorrectly presented to the immune system. This would then predispose to the inflammatory cascade that characterizes EoE. In this study, we also found higher levels of CXCL8 in the supernatants of patients with active EoE and reflux esophagitis compared with controls. CXCL8 is a powerful chemoattractant and activator of leukocytes and chemokine-mediated signaling pathways among others. Increased levels of CXCL8 have been previously documented in the esophageal mucosa of patients with gastroesophageal reflux disease^{18,19} and in EoE.²⁰ In the present study, we show that CXCL8 was elevated in the reflux group both at baseline and after stimulation with food extracts. We also detected an increased level in the active EoE group after food extract stimulation. We therefore suggest that CXCL8 may be regarded as a nonspecific inflammatory marker of esophageal barrier damage.

In our study, the IL-1ra levels were decreased in the unstimulated supernatants from active EoE compared with control biopsies. This agrees with a previous study where IL-1ra protein levels in EoE and normal biopsies were measured which demonstrated that IL-1ra was decreased in EoE.²¹ IL-1ra binds nontriggering to surface bound IL-1R which prevents the effect of IL-1. Upon stimulation with food extract, the level of IL-1ra doubled in the control group but remained low in the active EoE group. Since IL-1 is a highly inflammatory cytokine²² one could speculate that the capacity to produce an IL-1 antagonistic effect in EoE is impaired which might amplify the inflammatory response.

The main findings with GzmB, CXCL-8, and IL-1ra made us interested to identify a histological equivalent

of the biopsies. As we had limited biological material from our patients, we prioritized staining for GzmB which was the immunological marker with no previously known connection to EoE. Patients with active EoE showed an increased number of GzmB-positive cells upon microscopic examination, in contrast to the biopsies from both controls and EoE in remission. The GzmB-positive staining appeared to be localized in T cells, NK cells, and mast cells. Some GzmB granules could also be found extracellularly. Several of the cell types that commonly produce and/or release GzmB²³ were found in the biopsies from our patients with EoE upon microscopic examination. However, we could not identify a correlation between the number of eosinophils and GzmB, which may be interpreted as eosinophils are not the main producer of GzmB under these conditions.

In serum, the amount of GzmB appeared to be stable between the patients. We noticed a numerically increased level of GzmB in the active EoE group compared with the controls, however nonstatistically significant, which could be due to the small number of patients in the study, or that GzmB is limited to the esophagus. Previous studies have also failed to identify other markers that were raised in EoE patients compared with controls.²⁴ In the saliva there was a large variation among the study participants and no correlation to any specific patient group.

In summary, using a new method to evaluate immunological markers produced by esophageal mucosa *ex vivo*, we found that levels of barrier-damaging protease GzmB were higher in the supernatant of esophageal biopsies from patients with active EoE compared with those of controls, both before and after stimulation with food extracts. GzmB was also seen histologically in the esophageal biopsies from the patients with active EoE, but rarely in those from controls.

The finding of presence of the barrier damaging GzmB suggests a role in the pathogenesis of this disorder. As no connection previously has been described between EoE and GzmB, further studies need to be performed to investigate its significance in EoE.

ACKNOWLEDGMENTS

Dr Thulin was supported by project grants from Mjölkdroppen and from The Samariten Foundation for Pediatric Research. Dr Caroline Nilsson was founded by Swedish Asthma and Allergy Foundation. Posted history: This manuscript was previously posted to Authorea, <https://doi.org/10.22541/au.168602230.03593695/v1>.

CONFLICT OF INTEREST STATEMENT

The authors declare no conflict of interest.

ORCID

Helena Thulin  <https://orcid.org/0000-0002-6535-0736>

REFERENCES

- Lucendo AJ, Arias-González L, Molina-Infante J, Arias Á. Systematic review: health-related quality of life in children and adults with eosinophilic oesophagitis-instruments for measurement and determinant factors. *Aliment Pharmacol Ther.* 2017;46(4):401-409.
- Spergel JM, Brown-Whitehorn TF, Beausoleil JL, et al. 14 years of eosinophilic esophagitis: clinical features and prognosis. *J Pediatr Gastroenterol Nutr.* 2009;48(1):30-36.
- Blanchard C, Stucke EM, Rodriguez-Jimenez B, et al. A striking local esophageal cytokine expression profile in eosinophilic esophagitis. *J Allergy Clin Immunol.* 2011;127(1):208-217.
- Blanchard C, Wang N, Rothenberg M. Eosinophilic esophagitis: pathogenesis, genetics, and therapy. *J Allergy Clin Immunol.* 2006;118(5):1054-1059.
- Rochman M, Azouz NP, Rothenberg ME. Epithelial origin of eosinophilic esophagitis. *J Allergy Clin Immunol.* 2018;142(1):10-23.
- Cheng E, Souza RF, Spechler SJ. Tissue remodeling in eosinophilic esophagitis. *Am J Physiol Gastrointest Liver Physiol.* 2012;303(11):G1175-G1187.
- Papadopoulou A, Koletzko S, Heuschkel R, et al. Management guidelines of eosinophilic esophagitis in childhood. *J Pediatr Gastroenterol Nutr.* 2014;58(1):107-118.
- Hoofien A, Rea F, Espinheira MDC, et al. Systemic steroids have a role in treating esophageal strictures in pediatric eosinophilic esophagitis. *Dig Liver Dis.* 2020;53:324-328.
- Dellon ES, Liacouras CA, Molina-Infante J, et al. Updated international consensus diagnostic criteria for eosinophilic esophagitis: proceedings of the AGREE conference. *Gastroenterology.* 2018;155(4):1022-1033.
- Ismail-Beigi F, Horton PF, Pope 2nd CE. Histological consequences of gastroesophageal reflux in man. *Gastroenterology.* 1970;58(2):163-174.
- Ismail-Beigi F, Pope 2nd CE. Distribution of the histological changes of gastroesophageal reflux in the distal esophagus of man. *Gastroenterology.* 1974;66(6):1109-1113.
- Wang H, Huang Y, He J, Zhong L, Zhao Y. Dual roles of granzyme B. *Scand J Immunol.* 2021;94(3):e13086.
- Turner CT, Zeglinski MR, Richardson KC, et al. Granzyme B contributes to barrier dysfunction in oxazolone-induced skin inflammation through E-cadherin and FLG cleavage. *J Invest Dermatol.* 2021;141(1):36-47.
- Virchow JC. Eosinophilic esophagitis: asthma of the esophagus? *Dig Dis.* 2014;32(1-2):54-60.
- Simon D, Page B, Vogel M, et al. Evidence of an abnormal epithelial barrier in active, untreated and corticosteroid-treated eosinophilic esophagitis. *Allergy.* 2018;73(1):239-247.
- Amberger JS, Hamosh A. Searching online mendelian inheritance in man (OMIM): a knowledgebase of human genes and genetic phenotypes. *Curr Protoc Bioinformatics.* 2017;58:1-2.
- Ryu S, Lee KH, Tizaoui K, et al. Pathogenesis of eosinophilic esophagitis: a comprehensive review of the genetic and molecular aspects. *Int J Mol Sci.* 2020;21:7253.
- Rieder F, Biancani P, Harnett K, Yerian L, Falk GW. Inflammatory mediators in gastroesophageal reflux disease: impact on esophageal motility, fibrosis, and carcinogenesis. *Am J Physiol Gastrointest Liver Physiol.* 2010;298(5):G571-G581.
- Isomoto H, Inoue K, Kohno S. Interleukin-8 levels in esophageal mucosa and long-term clinical outcome of patients with reflux esophagitis. *Scand J Gastroenterol.* 2007;42(3):410-411.
- Haasnoot ML, Kleuskens MTA, Lopez-Rincon A, et al. In vivo and ex vivo inflammatory responses of the esophageal mucosa to food challenge in adults with eosinophilic esophagitis. *Allergy.* 2023;78(7):2044-2047.
- Abdulnour-Nakhoul SM, Al-Tawil Y, Gyftopoulos AA, et al. Alterations in junctional proteins, inflammatory mediators and extracellular matrix molecules in eosinophilic esophagitis. *Clin Immunol.* 2013;148(2):265-278.
- Dinarello CA. Interleukin-1. *Cytokine Growth Factor Rev.* 1997;8(4):253-265.
- Boivin WA, Cooper DM, Hiebert PR, Granville DJ. Intracellular versus extracellular granzyme B in immunity and disease: challenging the dogma. *Lab Invest.* 2009;89(11):1195-1220.
- Rabinowitz S, Yu L, Hahm E, et al. Pediatric eosinophilic esophagitis: searching for serologic markers. *Ann Clin Lab Sci.* 2022;52(4):642-650.

How to cite this article: Thulin H, Säfholm J, Lundahl J, Jovic V, Adner M, Nilsson C. Granzyme B is elevated in esophageal biopsies from children with eosinophilic esophagitis. *J Ped Gastro Nutr.* 2023;1-7. doi:10.1002/jpn3.12084