

# Simultaneous Echinococcal Superinfection in a Patient with Polycystic Liver Disease.

Ottavia Cicerone<sup>1</sup>, Raffaella Lissandrin<sup>1</sup>, Enrico Brunetti<sup>1</sup>, and Marcello Maestri<sup>1</sup>

<sup>1</sup>Università degli Studi di Pavia Facoltà di Medicina e Chirurgia

August 25, 2023

## Simultaneous Echinococcal Superinfection in a Patient with Polycystic Liver Disease.

Cicerone O.\*, Lissandrin R.^, Brunetti E.^, Maestri M.\*

\*: Fondazione IRCCS Policlinico San Matteo, Chirurgia Generale I, Pavia

Tropicali, Pavia

### Abstract:

Cystic echinococcosis, caused by *Echinococcus granulosus* eggs, is a parasitic zoonosis that typically affects humans through accidental ingestion. Polycystic liver disease is a condition characterized by the presence of multiple liver cysts and is often associated with polycystic kidney disease. Here, we present a case of a man in his 70s with a pre-existing diagnosis of polycystic liver disease. Radiological findings of a suspicious cyst in the S4 segment initially lacked serological evidence of echinococcosis; however, intraoperative confirmation revealed the presence of an echinococcal cyst. This article aims to explore both clinical conditions and highlight the therapeutic considerations for their management. Moreover, we discuss the significance of this unique case, emphasizing the possibility of the coexistence of these two pathologies.

### Background:

Echinococcosis is a widespread zoonotic disease caused by *Echinococcus* larvae, with *E. granulosus* being the most prevalent species. The disease is commonly found in regions with agricultural and pastoral activities but has also spread globally due to increasing globalization (1). Adult echinococcus parasites reside in the small intestines of definitive hosts (e.g., dogs) and excrete eggs in their feces. Intermediate hosts, including humans, become infected by accidentally ingesting these eggs. Once ingested, the eggs migrate through the portal venous or lymphatic pathways, primarily affecting the liver (80%) or lungs (less frequently other organs such as the spleen, brain, or kidneys) (2). Echinococcal cysts consist of two layers: the endocyst, formed by the parasite, and the pericyst, representing the host's reactive tissue. Accurate management of echinococcosis requires a multidisciplinary approach, involving clinical features, serology, and imaging, with ultrasound being the preferred diagnostic modality due to its ability to provide detailed cyst characteristics (3). Albendazole and mebendazole are the mainstay medical treatments, while surgical intervention is considered for patients with inadequate response to medical therapy or those with symptomatic or clinically significant cysts (2). Surgical options include total pericystectomy, endocystectomy with partial pericystectomy, or total endocystectomy, with the choice depending on cyst size, location, number, and patient's overall condition (4).

Polycystic liver disease is characterized by the progressive development of multiple cysts in the liver (5). The two most common genetic origins are autosomal dominant polycystic kidney disease (ADPKD), affecting both the kidneys and liver, and autosomal dominant polycystic liver disease (ADPLD), involving only the liver. Significant advancements have been made in understanding the molecular mechanisms underlying this

disease, leading to the development of promising drugs such as tolvaptan, a vasopressin V2 receptor inhibitor that slows cyst growth and preserves kidney function. Although liver function is generally preserved in polycystic liver disease, large cysts can cause compression symptoms and pain. Laparoscopic cyst fenestration is a preferred approach in such cases, although cyst recurrence is common (6).

### Case Presentation :

We report the case of a man with a known diagnosis of autosomal dominant polycystic kidney disease with concurrent liver cysts. He was referred to our center due to radiological suspicion of hepatic echinococcosis, despite negative serological findings. Given the lack of response to albendazole therapy and the diagnostic suspicion of echinococcosis, a multidisciplinary team considered surgical intervention for cyst removal. Intraoperatively, the polycystic liver was observed, and fenestration of two major simple cysts in segments 8 and 5 was performed. The cyst in segment 4 was found to be abscessed, leading to an endocystectomy with partial pericystectomy, confirming the diagnosis of echinococcal cyst. The surgical cavity was irrigated with a hypertonic solution, hemostasis was achieved using argon, and the absence of biliary fistulas was confirmed. A Jackson Pratt drain was placed, and postoperative therapy included albendazole to prevent recurrence of the parasite and piperacillin-tazobactam due to the cyst abscess in segment 4. Histological examination further confirmed that the cyst in segment 4 was an echinococcal cyst, while the other two were simple cysts. The patient developed postoperative pneumonia, which was successfully resolved. The patient had a one-week postoperative hospital stay, and subsequent outpatient follow-ups during the following months showed no complications or recurrence. The patient is currently under infectious disease surveillance (Fig.1).

### Discussion:

Echinococcosis is a disease caused by infection with parasites of the *Echinococcus* genus, which can form cysts primarily in the liver and lungs. In most cases, the diagnosis of echinococcosis can be relatively straightforward, but there are situations where the presence of other conditions can complicate the clinical picture.

In the case described in the report, the presence of polycystic disease, characterized by the formation of multiple cysts, masked the true nature of the hepatic cysts for a prolonged period. However, when the patient developed severe septic episodes, with a significant deterioration in their general condition, sepsis made the diagnosis more complex.

The negativization of specific indicators of *Echinococcus* infection may have been influenced by the presence of sepsis. In these complex situations, a multidisciplinary approach involving radiologists, infectious disease specialists, and surgeons is essential to reach an accurate diagnosis. In some cases, surgical exploration and drainage of the lesions may be necessary to confirm the presence of echinococcosis.

The possibility of concurrent *Echinococcus* infection should be considered in cases where there is polycystic disease with the presence of cysts exhibiting atypical features in the overall context. Multidisciplinary evaluation is crucial for making appropriate decisions regarding pharmacological therapy or invasive treatment, such as surgery or PAIR (puncture, aspiration, injection, re-aspiration), depending on the specific circumstances of the patient.

### Conclusion:

This case presents a unique occurrence of echinococcal superinfection in a background of polycystic liver disease. Typically, echinococcosis is not observed in the context of polycystic liver disease, possibly due to the unfavorable conditions for colonization by the worm. This previously unreported event highlights the importance of considering echinococcosis as a diagnostic possibility even in cases of polycystic liver disease. It also underscores the significance of a multidisciplinary approach in diagnosing and managing patients suspected of having a new cyst.

1. Budke CM, Carabin H, Ndimubanzi PC, Nguyen H, Rainwater E, Dickey M, et al. A systematic review of the literature on cystic echinococcosis frequency worldwide and its associated clinical manifestations. *Am*

J Trop Med Hyg. 2013;88(6):1011-27.

2. Olaizola P, Rodrigues PM, Caballero-Camino FJ, Izquierdo-Sanchez L, Aspichueta P, Bujanda L, et al. Genetics, pathobiology and therapeutic opportunities of polycystic liver disease. Nat Rev Gastroenterol Hepatol. 2022;19(9):585-604.

3. Rinaldi F, Brunetti E, Neumayr A, Maestri M, Goblirsch S, Tamarozzi F. Cystic echinococcosis of the liver: A primer for hepatologists. World J Hepatol. 2014;6(5):293-305.

4. Bektasoglu HK, Hasbahceci M, Tasci Y, Aydogdu I, Malya FU, Kunduz E, Dolay K. Comparison of Laparoscopic and Conventional Cystotomy/Partial Cystectomy in Treatment of Liver Hydatidosis. Biomed Res Int. 2019;2019:1212404.

5. Pitchaimuthu M, Duxbury M. Cystic lesions of the liver-A review. Curr Probl Surg. 2017;54(10):514-42.

6. van Aerts RMM, van de Laarschot LFM, Banales JM, Drenth JPH. Clinical management of polycystic liver disease. J Hepatol. 2018;68(4):827-37.

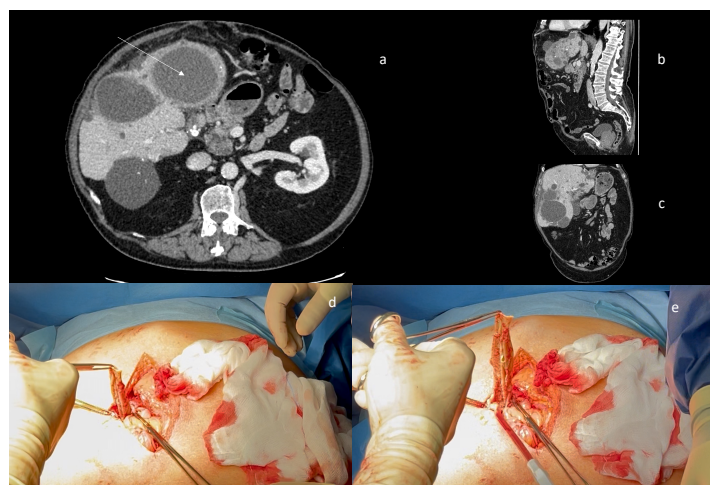


Fig 1  
a, b, c: CT scan of multiple liver cysts. The arrow points the echinococcal one  
d, e: the opening of the cyst demonstrated the endocyst of the parasite