Use of surgical grafting as a part of multidisciplinary treatment for a patient treated with fixed orthodontic therapy to improve treatment outcomes.

Hoang Viet[1], Tran Phuoc[1], Hoang Tuyen[1], and anand marya[2]

[1]Saigon Dental Private Hospital
[2]University of Puthisastra

August 30, 2023

Introduction

The presence of anterior diastemas may compromise the esthetics of a patient's smile, causing mental and social trauma in many patients. In such patients' careful consideration must be given to the etiology behind the presence of the diastemas before a treatment plan can be formulated. Individual treatment planning is essential in such cases and may require more than just fixed orthodontic intervention. Periodontal, surgical, and prosthodontic treatments are sometimes required to ensure a successful outcome (1,2).

Case Report

Diagnosis and etiology

The patient was a 30 years-old woman with a chief complaint of protrusive lips, proclined

maxillary incisors, anterior spacing, and recession on mandibular incisors. Extra-orally, she had a convex profile with an acute nasolabial angle, a strain on the circumoral muscles while closing her mouth, and a proclination of the upper incisors was observed when the patient smiled. No symptom of temporomandibular disorders was detected (Figure 1a, 1b).

Intraorally, the patient had a Class I molar and canine relation on the right side, a Class I molar and a Class II canine relationship on the left side, and peg-shaped lateral incisors. The patient only had 3 lower incisors present, diastemas in the maxillary and mandibular anterior teeth because of the tongue's position, and recession on the lower incisors. The upper and lower arch forms were typically developed, and a flat Curve of Spee was observed. The patient demonstrated Bolton's tooth size discrepancies because of the 3 lower incisors. The upper midline coincided with the facial midline. The lateral cephalometric analysis showed a skeletal Class I jaw relationship with proclined upper and lower incisors. Both the upper and lower lips were in front of the E-line (Figure 1c).

Treatment plan

The treatment plan was multidisciplinary, involving fixed orthodontics, periodontics, and prosthodontic interventions in stages. 3D simulation was planned for the patient to analyze the size of the 3 lower incisors.

Stage I: Fixed Orthodontic therapy

In the upper arch the anterior segment was distalized using 2 mini screws and in the lower arch, retraction was carried out using a sliding technique with reverse curve 17x25 SS wire and power chains so as to control the tipping of the upper and lower incisors (Figure 2). Class III elastics were utilized to improve the anchorage on the lower arch. The goal of orthodontics treatment was to reduce the proclination of the upper and

lower anterior teeth, close the diastema on the upper, make the space on the lower smaller for prosthodontic intervention and achieve good occlusion. After treatment, restorations were placed on the 3 mandibular incisors.

Stage II: Gingival grafting

After a 1-month waiting period post debonding of the braces, gingival grafting was carried out using the subepithelial CTG technique (Conective tissue grafting tunnel technique) in the mandibular anterior region (Figure 3). The connective tissue graft was acquired from the right maxillary in the area mesial to the premolars and the first maxillary molar. 2% Lignocaine hydrochloride with adrenaline was used for local anesthesia, and then the first incision was given parallel to the long axis of the palate. The thickness of the flap was kept sufficient to ensure no tearing of the tissues. Root planning was done on the lower incisors before placement of the graft.

The harvested graft was sutured over the exposed root surfaces. Pressure was applied over the graft for a few minutes, and a periodontal pack was placed for healing. The patient was recalled after 2 weeks, the sutures were removed, and the healing appeared normal (Figure 3b, 3c).

Stage III: Restoration

After graft healing, esthetic restorations were placed in the mandibular arch from left to right lower canines (3,4,5). These were also intended to help close the diastema and provide good retention for the 3 lower incisors (Figure 4a, 4b, 4c).

Treatment results

All initial treatment objectives were achieved with a well-aligned dentition, closure of all the diastemas, good occlusion, and improved facial aesthetics.

The whole treatment was achieved by retraction of both upper and lower lips, resulting in a passive lip seal and relatively straight profile after treatment. Good root parallelism was achieved with minimal root resorption. There was an improvement in the incisor inclination and soft tissue profile, particularly across the E-line and the nasolabial angle (Igure 4c, 4d).

Discussion

In the current scenario, many treatment options are available to the patients for space closure and improving esthetics. Restorations and surgical grafts are some of the commonly available options that can drastically change the patient's smile (6,7). These economical techniques can be carried out chairside, requiring much fewer appointments than other options. Dentists have utilized multidisciplinary approaches to ensure much better esthetic results than those obtained with singular approaches.

Conclusion

The present multidisciplinary approach combines fixed orthodontics, periodontal surgery, and prosthodontics to manage and improve a patient's smile and facial esthetics.

Ethical Statement

Because this report involves no experiment, ethics approval was not required.

Acknowledgment

The authors would like to thank the patient for giving their consent.

Patient consent

Written informed consent was obtained from the patient to publish this report in accordance with the journal's patient consent policy.

Conflict of Interest

The authors report no conflict of interest.

Author contributions: VH: patient treatment AM: diagnosis and treatment planning VH and AM: manuscript preparation, review and editing.

References

1. Furuse AY, Herkrath FJ, Franco EJ, Benetti AR, Mondelli J. Multidisciplinary management of anterior diastemata: clinical procedures. Pract Proced Aesthet Dent. 2007 Apr;19(3):185-91; quiz 192.
2. Furuse AY, Franco EJ, Mondelli J. Esthetic and functional restoration for an anterior open occlusal relationship with multiple diastemata: a multidisciplinary approach. J Prosthet Dent. 2008 Feb;99(2):91-4.
3. Barreto BC, Lima AF, Catelan A, da Silva GR, Gaglianone LA, Martins LR, Aguiar FH, Soares CJ. A complete esthetic approach with multiple diastemata in anterior teeth: 1-year follow-up. Gen Dent. 2013 Mar-Apr;61(2):54-6.
4. de Oliveira AA, Vale GA, Almeida LDM, Saltarelo RC, Veríssimo C. Multidisciplinary approach for the closure of multiple diastemata with composite resin. Int J Esthet Dent. 2022 Sep 1;17(3):308-322.
5. Manauta J, Salat A, Monterubbianesi R, Tosco V, Devoto W, Orsini G, Putignano A. Advances in diastema closure and tooth shape change using direct composite restorations: the Front Wing Technique. Int J Esthet Dent. 2022 Nov 25;17(4):378-393.
6. Ittipuriphat I, Leevailoj C. Anterior space management: interdisciplinary concepts. J Esthet Restor Dent. 2013 Feb;25(1):16-30. doi: 10.1111/j.1708-8240.2012.00515.x. Epub 2012 May 29.
7. Rathore N, Desai A, Trehan M, Jharwal V, Puzhankara L, Marya A. Ortho-Perio Interrelationship. Treatment Challenges. The New York State Dental Journal. 2015 Aug 1;81(5):42-7.

Figure Legends

Figure 1A: Pre-treatment Intra oral Images of the patient

Figure 1B: Pre-treatment Extra Oral Images of the patient

Figure 1c: Pre-treatmentXrays

Figure 2: Fixed orthodontic treatment progress

Figure 3a: Surgical grafting using subepithelial CTG

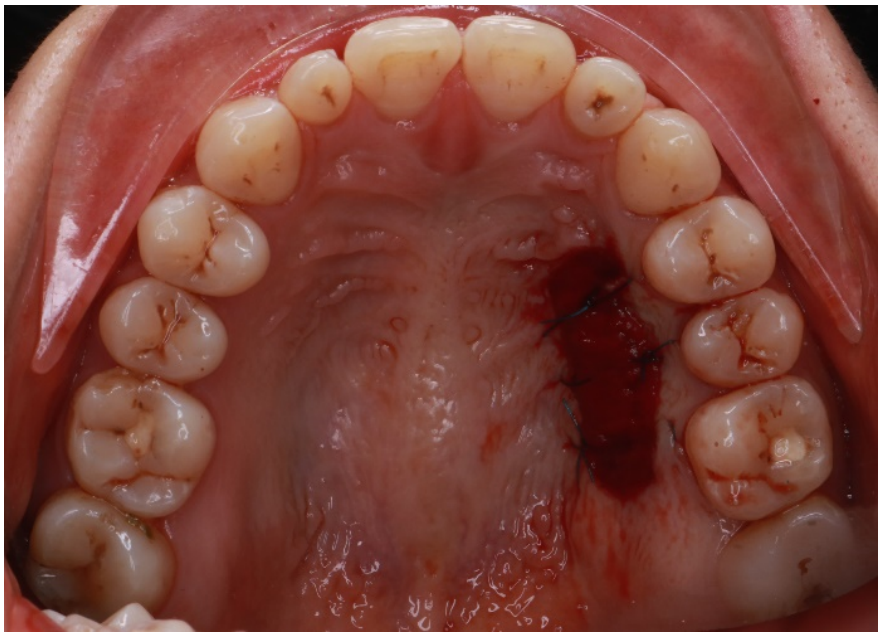

Figure 3b: Follow up after 2 weeks CTG

Figure 3c: Follow up after after 1 month

Figure 4a: Post-treatment Intra oral Images of the patient

Figure 4b: After esthetic restorations

Figure 4c: Extra oral pictures post treatment

Figure 4D: Post treatment X rays