

# Ulcerative colitis associated mononeuritis multiplex in 75-year-old patient: rare case report

omid pourbagherian<sup>1</sup>, Mehdi Jafarpour<sup>1</sup>, Sepideh Tahsini<sup>1</sup>, Amirtaher Eftekharsadat<sup>2</sup>, and Maryam Javid<sup>1</sup>

<sup>1</sup>Tabriz University of Medical Sciences

<sup>2</sup>Department of Pathology, Tabriz University of Medical Sciences, Tabriz, Iran

November 1, 2023

## Introduction

Inflammatory bowel disease (IBD) refers to a collection of chronic, idiopathic inflammatory/autoimmune disorders of the gastrointestinal tract characterized by relapsing and remitting episodes(1). The two main types of IBD are Crohn's disease and ulcerative colitis which lead to a various type of debilitating symptoms such as abdominal pain, rectal bleeding, weight loss, and diarrhea. The precise mechanisms underlying IBD pathogenesis remain unclear but are thought to involve a dysfunctional interplay between host genetics, the intestinal immune system, and environmental factors(2). Current evidence suggests IBD results from an aberrant immune response directed against commensal gut bacteria in genetically susceptible individuals(3). Multiple genetic loci have been implicated in IBD risk, including genes involved in epithelial barrier function, microbial sensing, and immunoregulation. However, genetics alone cannot explain IBD's rising incidence, highlighting the likely contribution of environmental risk factors like diet, smoking, medications, stress, and the microbiome. Ongoing research aims to better delineate the complex immunopathogenesis of IBD in order to identify improved diagnostic markers, prognostic indicators, and therapeutic targets(4). Moreover, Individuals diagnosed with IBD frequently encounter an array of difficulties that extend beyond the gastrointestinal system. One such challenge is the emergence of mononeuritis multiplex. This association between ulcerative colitis and mononeuritis multiplex underscores the intricate and multifaceted nature of these autoimmune disorders. The occurrence of symptoms of one condition in individuals afflicted by the other warrants careful examination by medical specialists. This necessitates a thorough investigation into the underlying reasons and the implementation of preventive measures. In this case report, we will report a patient who has encountered ulcerative colitis related to mononeuritis multiplex.

## Case presentation

A 75-year-old male patient, with a prior medical history including long-standing hypertension, recurring episodes of peripheral joint arthritis, leg skin lesions reminiscent of erythema nodosum, and persistent chronic diarrhea over the past two years, was recently hospitalized at the rheumatology department of Imam Reza Hospital in Tabriz. His admission was prompted by a worsening of diarrhea and the development of polyarthritis in the peripheral joints. Furthermore, he exhibited distinctive palm skin lesions (as depicted in Figure 1), along with sensations of tingling and paresthesia in his extremities and an increase in blood creatinine levels. Throughout the patient's hospital stay, a series of diagnostic assessments were conducted, encompassing procedures such as colonoscopy (as shown in Figure 2), Electromyography and nerve conduction studies (EMG-NCS), echocardiography, renal ultrasonography, and standard hematological analyses (Table 1). Notably, the colonoscopy result was: Multiple ulcers with congested and erythematous and friable mucosa, prompting a subsequent intestinal biopsy that yielded findings consistent with a diagnosis of ulcerative colitis (Figure 3) . The result of the EMG-NCS was reported as follows: moderate axonal sensory

motor polyneuropathy with superimposed newly onset left median and ulnar neuropathy compatible with mononeuritis multiplex neuritis. In echocardiography EF (Ejection Fraction) 35-40% with normal LV (Left Ventricular Size) and RV (Right Ventricular) size was reported. Ultrasound of kidney and urinary tract did not reveal any abnormalities and shape, size, and echogenicity of the kidneys were reported as normal.

Based on a comprehensive array of diagnostic findings, encompassing both colon and skin and nerve biopsies, the patient's medical condition was ascertained. The colon biopsy confirmed the presence of active ulcerative colitis while excluding any associated vasculitis-related indicators. Simultaneously, the skin and nerve biopsy yielded no indications of vasculitis. Consequently, the patient received a formal diagnosis of ulcerative colitis concomitant with mononeuritis multiplex and underwent the following therapeutic regimen.

The initial phase of treatment involved the administration of corticosteroid pulse therapy at a dosage of 1 gram per day, administered consecutively for three days. Additionally, the patient received a 750 mg ampoule of cyclophosphamide as part of the prescribed therapeutic protocol.

**Pulse Corticosteroid :** The treatment began with a high dose of corticosteroids \ administered intravenously at 1 gram per day for three consecutive days. This approach is aimed at rapidly reducing inflammation.

**Cyclophosphamide :** On the same day, the patient received an injection of cyclophosphamide at a dose of 750 mg. Cyclophosphamide is an immunosuppressive medication often used to treat vasculitis by suppressing the overactive immune response.

**Mesalamine:** Based on a consultation with a gastrointestinal specialist, the patient was prescribed mesalamine

During the hospitalization, the patient's diarrhea ceased, and their hydration improved. Additionally, their creatinine levels decreased(creatinine =1.1), indicating a positive response to treatment. As a result, the patient was discharged from the hospital with the following medications:

**Prednisolone :** The patient was prescribed prednisolone at a dose of 20 mg three times a day (TDS).

**Mesalazine :** Mesalazine is another medication commonly used in the treatment of IBD.

**Cotrimoxazole and Monthly Cyclophosphamide Injection :** The patient received cyclophosphamide injections on a monthly basis.

In accordance with the patient's recent follow-up conducted over the past 20 days, it is notable that recurrent episodes of diarrhea have not been reported. Additionally, the patient has shown substantial amelioration in parathesis and tingling symptoms, and notably, the previously evident arthritis has demonstrated complete resolution. These observed clinical improvements signify a promising response to the treatment and suggest a positive trajectory in the management of the patient's condition.

## Discussion

In this case report, we highlight and present a unique and uncommon clinical scenario involving 75-year-old patient with a history of ulcerative colitis. To the best of our knowledge this is the first case of ulcerative colitis associated mononeuritis multiplex. The exact etiology and cause of ulcerative colitis remain incompletely understood, and it is believed to be a complex interplay of genetic, environmental, immunological, and microbial factors(5). Mononeuritis multiplex is a rare neurological disorder characterized by multifocal nerve damage(6). These two distinct diseases may have some connections in the context of extraintestinal manifestations of UC and autoimmune processes. Ulcerative colitis (UC) and mononeuritis multiplex appear to stem from similar underlying processes - an aberrant immune reaction. The inflammatory bowel disease known as UC arises when the immune system overreacts within the gastrointestinal tract, provoking inflammation and sores in the colon. Mononeuritis multiplex occurs due to the immune system assaulting peripheral nerves, impairing neurological function. Although UC centers around the digestive system while mononeuritis multiplex involves nerve damage, the common autoimmune component points to a plausible

association between these two conditions. Uncovering the precise immune pathways responsible could clarify how an overactive immune system in UC may occasionally give rise to nerve inflammation and injury remotely, manifesting as mononeuritis multiplex. Elucidating the mechanisms linking intestinal autoimmunity with neuronal autoimmunity will enable better understanding of the scope of extraintestinal manifestations in inflammatory bowel disease.

The precise etiology and pathophysiology underlying both ulcerative colitis (UC) and mononeuritis multiplex remain incompletely elucidated, likely involving a constellation of factors(7). Given the intricate nature of autoimmune diseases and their potential for systemic effects, overlapping mechanisms could potentially contribute to the pathogenesis of both conditions. However, direct causal links between UC and mononeuritis multiplex are yet to be established, and they constitute distinct clinical entities. Nevertheless, indirect associations such as autoimmune processes and shared immune system involvement imply that individuals with UC may be at heightened risk for developing other autoimmune diseases, including mononeuritis multiplex. Therefore, UC patients presenting with unexplained neurological signs and symptoms warrant comprehensive diagnostic workup to exclude neurological complications like mononeuritis multiplex, followed by prompt initiation of appropriate therapy. Further research into the complex immunological interactions in UC and the mechanisms underlying secondary systemic manifestations like mononeuritis multiplex will provide greater insight into the spectrum of extraintestinal disease in patients with inflammatory bowel disease.

R. Okiyama et.al presented a case of a 40-year-old woman experienced rectal bleeding, diarrhea, weight loss, and tenesmus, leading to a diagnosis of ulcerative colitis affecting the ascending colon to the rectum. Initial treatment with oral salazosulfapyridine (SASP) was effective, resulting in a remission lasting 7 years. UC exacerbation occurred, prompting treatment with higher SASP and prednisolone. SASP was stopped due to suspected side effects, after which the patient experienced a severe UC relapse, accompanied by paresthesia and weakness in the lower extremities and right hand. This patient presented with acute mononeuritis multiplex characterized by distinct right-sided predominance. Nerve conduction studies and biopsy supported axonal degeneration as the primary neuropathological process. Notably, the neuropathy's development and course closely paralleled UC activity, suggesting a strong correlation. This case represents a unique manifestation of neuropathy associated with UC(8).

F. Tripodi Cutri et.al reported ulcerative colitis associated with leukocytoclastic vasculitis of the skin. Ulcerative colitis may be associated with a number of skin lesions such as erythema nodosum and pyoderma gangrenosum. They describe an unusual case of a 33-year-old-caucasian male with ulcerative colitis and skin lesions diagnosed as leukocytoclastic vasculitis. An initial treatment with oral deflazacort led to little benefit, while treatment with oral Mesalazine caused remission of the skin and intestinal manifestations in 2 weeks(9).

Scott R Levin et.al presented a prime example of the diverse extraintestinal manifestations that can accompany inflammatory bowel disease. As illustrated by the 58-year-old female described, ulcerative colitis may present atypically with a constellation of cutaneous, ocular, arthritic and hematologic abnormalities prior to the onset of gastrointestinal symptoms. The tender skin lesions with characteristic palmoplantar distribution, biopsy findings showing neutrophilic infiltration, and resolution with ulcerative colitis treatment collectively confirm the diagnosis of neutrophilic dermatosis(10). This rare dermatosis highlights the neutrophil-mediated inflammation that likely underpins many extra-intestinal manifestations of IBD. The episodic course and response to systemic steroids aligns with previous reports of neutrophilic dermatoses in IBD.

## Conclusion

In conclusion, our case presented a A 75-year-old male patient which developed Ulcerative colitis associated mononeuritis multiplex as a rare case

## Acknowledgments

The authors express their gratitude for the valuable contribution made by the patient in providing biopsy

and blood donation.

The authors appreciate support provided by Imam Reza Hospital, Tabriz, Iran.

**Author contributions**

All authors approved the final manuscript.

**Availability of data and material**

Considering that this study is about a rare disease availability to patients and data may hard to some extent.

**Funding**

Not applicable

**Competing interests**

The authors declare that they have no competing interests

**Ethical approval**

This study has been performed according to the Declaration of Helsinki.

**Consent**

Written informed consent was obtained from the patient to publish this report in accordance with the journal’s patient consent policy.

**Corresponding author e-mail address**

jafarpourmehdi1360@gmail.com

**Tables**

**Table 1.** Laboratory parameters of the patient

Test	Result	Normal range	Unit
HBS Ag*	Negative	Negative	Qualitative
HCV Ab*	Negative	Negative	Qualitative
HIV Ab*	Negative	Negative	Qualitative
Serum protein *electrophoresis	Normal	-	IU/MI
ESR*	110	For males: 0-15 mm/hr (millimeters per hour) For females: 0-20 mm/hr	mm/hr
CRP*	300	Less than 10 mg/L	mg/L
F ANA*	Negative	Negative	Qualitative
C ANCA*	Negative	Negative	Qualitative
P ANCA*	Negative	Negative	Qualitative
S/C*	Negative	Negative	Qualitative
Anti SSA	Negative	Negative	Qualitative
Anti SSB	Negative	Negative	Qualitative
Anti dsDNA*	Negative	Negative	Qualitative
S/E*	WBC: Moderate RBC: Moderate	Negative	Qualitative
Na*	140	135 to 145	µq/L
K*	4.1	3.5 to 5.0	µq/L
C3*	102(90-180)	90 - 180	mg/dL

Test	Result	Normal range	Unit
C4*	15 (10-40)	10 - 40	mg/dL
Urine analysis*	RBC: 4-5 Protein: Trace	-	-
Urea*	138	0.7 to 1.3	mg/dL
Creatinine*	4.5	0.6 to 1.1	mg/dL
AST*	35	10-40	U/L
ALT*	24	7-56	U/L
ALKP*	571	44-147	U/L
TSH*	2.8 (Normal)	0.4 - 4.0	mIU/L
WBC*	18200	4,500 to 11,000	cells/ $\mu$ L
MCV*	91	80-100	fl
HB*	9.8 g/dl	males: 13.8 to 17.2 g/dL females: 12.1 to 15.1 g/dL	g/dL
RF*	Negative	-	-
PLT*	214000	150,000 to 450,000	platelets/ $\mu$ L
Anti-CCP*	Negative	-	-
Fe	26	70 to 175 mcg/dL	mcg/dL
Ferritin	Normal		
TIBC	Normal		

+HBS Ag: Hepatitis B Surface Antigen, HCV Ab: Hepatitis C Virus Antibodies, HIV Ab: Human, ESR: Erythrocyte Sedimentation Rate, CRP: C-Reactive Protein, F ANA: Fluorescent Antinuclear Antibody, C ANCA: Cytoplasmic Antineutrophil Cytoplasmic Antibody, P ANCA: Perinuclear Antineutrophil Cytoplasmic Antibody, Anti-smith ab, Anti SSA: Anti-Sjögren's Syndrome A Antibodies, Anti SSB: Anti-Sjögren's Syndrome B Antibodies, Anti dsDNA: Anti-Double-Stranded DNA Antibodies, C3: Complement Component 3, C4: Complement Component 4, AST: Aspartate Aminotransferase, ALT: Alanine Aminotransferase, ALKP: Alkaline Phosphatase, LDH: Lactate Dehydrogenase: White Blood Cell Count, HB: Hemoglobin, MCV: Mean Corpuscular Volume, PLT: Platelet Count

## Figures

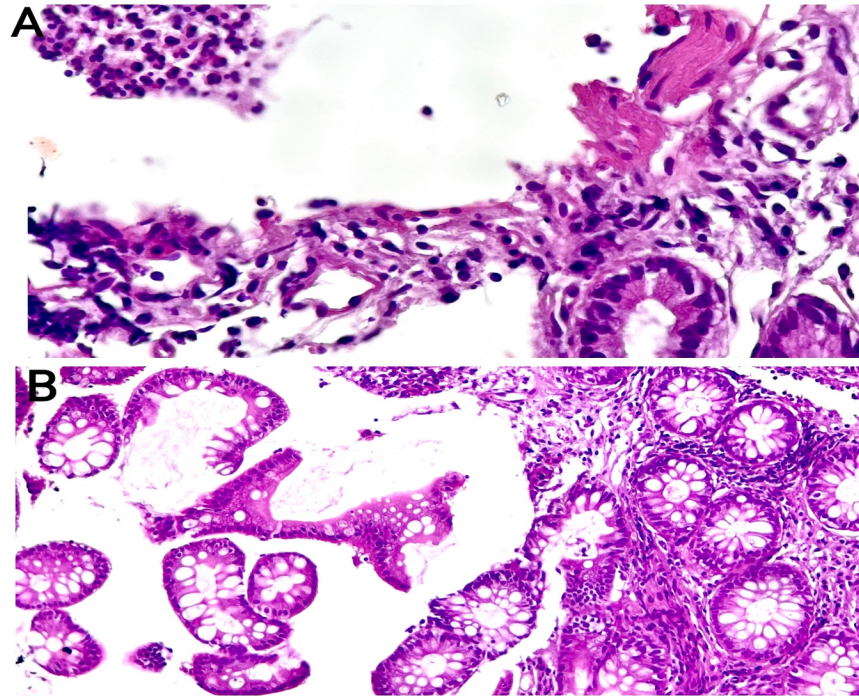
Fig1: Distinctive palm skin lesions

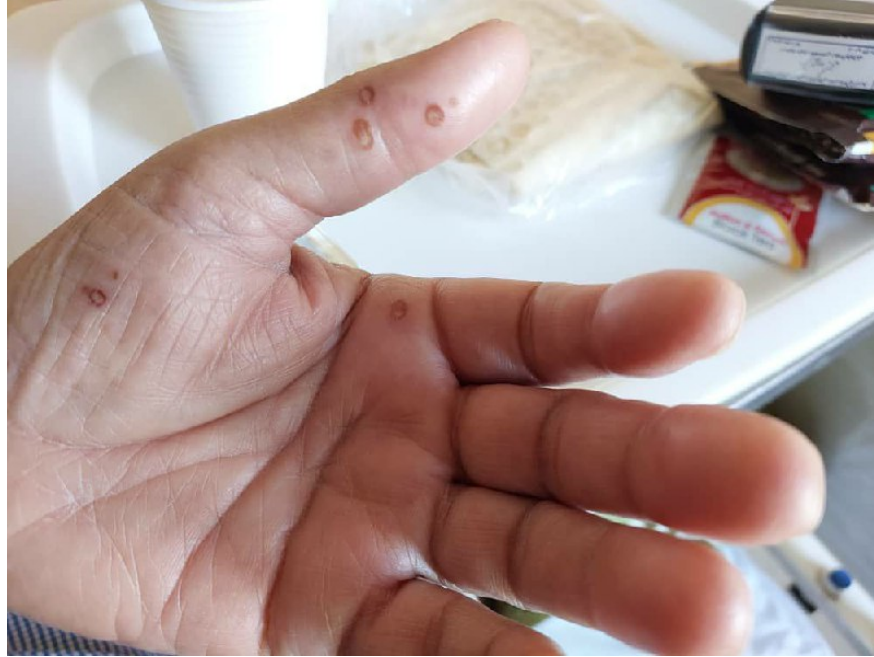

Fig2: Colposcopy of Patient

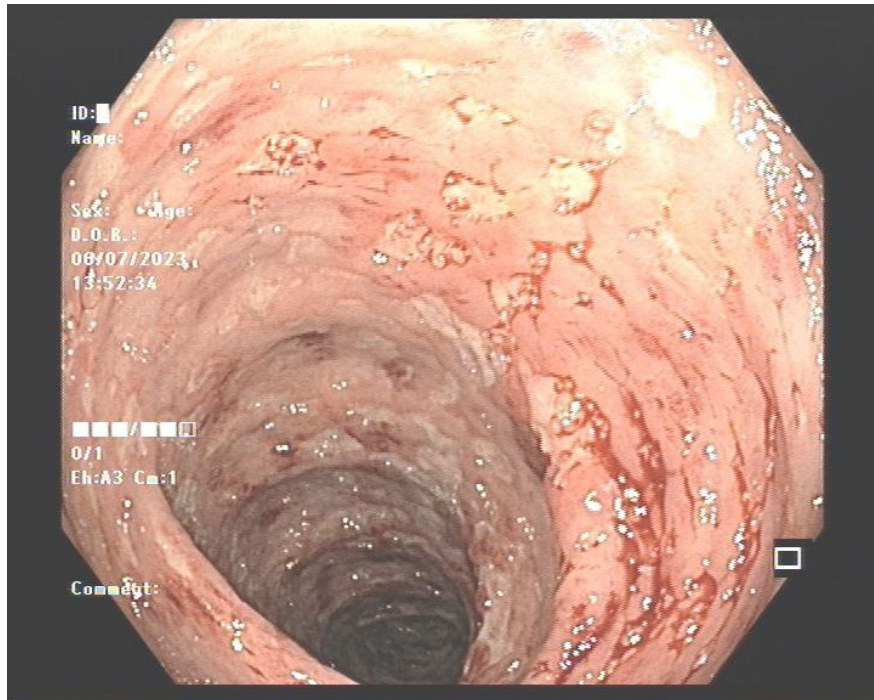

Fig3: Intestinal biopsy from patient, microscopic view (histologic) of a biopsy of the intestine (A&B) (H&E, ×50)



## References

1. Saez A, Herrero-Fernandez B, Gomez-Bris R, Sánchez-Martinez H, Gonzalez-Granado JM. Pathophysiology of inflammatory bowel disease: innate immune system. *International Journal of Molecular Sciences*. 2023;24(2):1526.
2. Ramos GP, Papadakis KA, editors. *Mechanisms of disease: inflammatory bowel diseases*. Mayo Clinic Proceedings; 2019: Elsevier.
3. Schirmer M, Garner A, Vlamakis H, Xavier RJ. Microbial genes and pathways in inflammatory bowel disease. *Nature Reviews Microbiology*. 2019;17(8):497-511.
4. Wijnands AM, de Jong ME, Lutgens MW, Hoentjen F, Elias SG, Oldenburg B, et al. Prognostic factors for advanced colorectal neoplasia in inflammatory bowel disease: systematic review and meta-analysis. *Gastroenterology*. 2021;160(5):1584-98.
5. Esiyok A, Yavasoglu I, Sargin G, Coskun A, Kadikoylu G, Meteoglu I, Bolaman Z. A rare etiology of fever of unknown origin: ulcerative colitis. *European Geriatric Medicine*. 2013;4(6):414-5.
6. Hellmann DB, Laing TJ, Petri M, Whiting-O'keefe Q, Parry GJ. Mononeuritis multiplex: the yield of evaluations for occult rheumatic diseases. *Medicine*. 1988;67(3):145-53.
7. Kaur A, Goggolidou P. Ulcerative colitis: understanding its cellular pathology could provide insights into novel therapies. *Journal of inflammation*. 2020;17:1-8.
8. Okiyama R, Yamada M, Tamaki M, Orimo S, Arai M. Mononeuropathy multiplex with ulcerative colitis. *Internal medicine*. 1993;32 8:651-4.
9. Cutrì FT, Salerno R, Schiavo AL, Gravina AG, Romano M, Ruocco E. Ulcerative colitis associated with leukocytoclastic vasculitis of the skin. *Digestive and liver disease : official journal of the Italian Society of Gastroenterology and the Italian Association for the Study of the Liver*. 2009;41 7:e42-4.

10. Fine S. Extraintestinal Manifestations of Inflammatory Bowel Disease. Rhode Island medical journal. 2022;105 9:13-9.

**Hosted file**

figure.docx available at <https://authorea.com/users/617984/articles/683695-ulcerative-colitis-associated-mononeuritis-multiplex-in-75-year-old-patient-rare-case-report>

**Hosted file**

table.docx available at <https://authorea.com/users/617984/articles/683695-ulcerative-colitis-associated-mononeuritis-multiplex-in-75-year-old-patient-rare-case-report>