

Efficiency of Curcumin in Preventing Ischemia-Reperfusion Damage in Aortic Vascular Endothelial Cells

Mehmet Aydin¹, Sakine Sönmez¹, Nazim Kankilic¹, Ezhar Korkmaz¹, and İsmail Koyuncu¹

¹Harran University

April 05, 2024

Abstract

Backgrounds: Turmeric (*Curcuma longa*, Turmeric, Indian saffron) is a widely used herb in China and India. Curcumin, the most active ingredient in this plant, has been shown to have protective effects against ischemia-reperfusion damage. In our study, the effects of Curcumin on vascular endothelium in ischemia-reperfusion injury in the abdominal aorta were investigated. **Methods:** Fifteen Wistar-albino rats were divided into three groups as sham, control and treatment (Curcumin group). Abdominal aortic ischemia was applied to the control and Curcumin groups for 60 minutes. Curcumin was administered intraperitoneally at a dose of 200 mg / kg to the Curcumin group 5 minutes before reperfusion. Afterwards, a 60-minute reperfusion period was applied to both groups. Total antioxidant capacity (TAC), total oxidant status (TOS) and oxidative stress index (OSI) in blood serum were measured. Aortic endothelial tissue was examined in a histopathological way and endothelial damage was scored and compared. **Results:** It was observed that TAC, TOS and OSI activities in blood samples were significantly decreased in sham and curcumin groups compared to the control group ($p < 0.05$). There was no difference in vascular endothelial damage scores in Sham, curcumin and control groups ($p > 0.05$). Histopathological examination revealed no lesions in the curcumin and control groups. Curcumin administration reduces oxidative stress in ischemia-reperfusion injury. **Conclusion:** It was thought that the aortic tissue was more resistant to I / R damage due to possible perfusion differences. In future studies, the effects of Curcumin on vascular endothelium in ischemia-reperfusion injury will be understood more.

INTRODUCTION

As a result of ischemia occurring in tissues for various reasons, cellular energy stores are emptied, and cell death occurs as a result of the accumulation of toxic metabolites. It is necessary to provide blood flow to ischemic tissue for both regeneration of the cell and removal of toxic metabolites. Reperfusion injury occurs during the re-bleeding period following the ischemia period. Free oxygen radical (ROS) derivatives, which are rapidly formed by the presentation of molecular oxygen into the cell, are one of the most causing factors¹. Ischemia-reperfusion (I / R) damage in tissues may be caused clinically by transplantation surgery, aortic cross clamp applications, tourniquet application, free tissue transfers, acute compartment syndrome, and replantation of the amputated extremity^{2,3}. During ischemia, toxic oxygen radicals are produced in ischemic tissue. After reperfusion, free oxygen radicals and superoxide radicals cause endothelial damage and increased vascular permeability. In addition, activated adhesion molecules and cytokines also initiate the systemic inflammatory response⁴.

CURCUMIN

Curcumin can be found in Turmeric (hind saffron), which is used as a spice that gives yellow color. Turmeric (*Curcuma longa*, Turmeric, Indian saffron) is a herbaceous perennial herb with yellow flowers, large leaves and tubers belonging to the ginger family, widely grown in China and India. It is produced from the yellow powder of the tropical plant *Curcuma longa* (Zingiberaceae). The most active ingredient of turmeric spice is curcumin. Curcumin is generally classified as natural and artificial. Curcumin, demethoxycurcumin,

bisdimethoxycurcumin are naturally occurring compounds ^{5,6} (Figure-1). Curcumin is a natural substance that does not show toxic properties in overdose and has been used in local / topical and general use in eastern societies, especially in Indian and Chinese traditional medicine, for skin, gastrointestinal diseases and wound healing. However, the biological effect and molecular mechanisms of Curcumin have been tried to be explained with epidemiological, clinical and animal studies^{7,8}.

The antioxidant effects of curcumin are similar to those of vitamins C and E ⁹. By facilitating the removal of many reactive oxygen radicals, especially superoxide anion radicals, nitrogen dioxide radicals and hydroxyl radicals, this increases the antioxidant ability. It has been shown to increase the activity of many antioxidant enzymes such as catalase, superoxide dismutase (SOD), glutathione peroxidase (GPx) and both oxygenase-1 (OH-1) ¹⁰. It also suppresses the synthesis of inflammatory prostaglandins that increase oxidant load ¹¹. One of curcumin's significant properties is that it offers defense against processes of carcinogenesis. It increases the production in the kidneys and liver of xenobiotic detoxifying enzymes and decreases tumor tissue angiogenesis by inhibiting metalloproteinases ^{12,13}. In the cardiovascular system, very low-density lipoprotein (VLDL), low-density lipoprotein (LDL), cholesterol and triglyceride levels have been shown to decrease ¹⁴. Furthermore, by inhibiting both the aggregation and adhesion of platelets via cGMP via NO, it prevents thrombus formation ^{15,16}.

Due to its anti-inflammatory and antioxidant effects, curcumin is believed to be useful in preventing I/R damage to vascular endothelial cells. In our research, we attempted to determine how much curcumin decreases systemic oxidant effects and vascular endothelial damage in rats with experimental I/R damage for this function.

MATERIALS AND METHODS

Our study was approved by the Animal Experiments Local Ethics Committee dated 24.09.2013 (the approval decision of the Harran University Animal Experiments Local Ethics Committee dated 30.04.2012, numbered B.30.2. HRÜ.0.05.07.00/270) was published in the Official Gazette by the Ministry of Environment and Forestry. It was conducted in accordance with the Regulation on the Working Procedures and Principles of Animal Experiments Ethics Committees published in the copy of the Law No. 2622 dated July 6, 2006, and the Directive of the Harran University Animal Experiments Local Ethics Committee.

Establishing Study Groups

Their average weight is 250- 300- 240 gr. 15 Wistar-albino rats were randomly divided into 3 groups of equal numbers (n=5). Rats were kept at room temperature and 12 hours light-12 hours dark before the study. All rats were fed with tap water and standard rat feed under standard conditions. Feeding of all rats was stopped 8 hours before the intervention.

Experimental Groups and Protocol

Experimental Groups and Protocol were formed in three groups. Group 1 (Sham, n = 5): During the study, no procedure was performed except for anesthesia. Tissue and blood samples were taken at an hour corresponding to the end of the reperfusion period. Group 2 (Control, I / R, n = 5): After anesthesia, 60 minutes of ischemia and 60 minutes of reperfusion were applied to the infrarenal abdominal aorta, no medication was given. Tissue and blood samples were taken at an hour corresponding to the end of the reperfusion period. Group 3 (I / R + Curcumin, n = 5): 60 minutes of ischemia and 60 minutes of reperfusion were applied to the infrarenal abdominal aorta after anesthesia. 200 mg/kg Curcumin was administered intraperitoneally 5 minutes before the tourniquet was opened. (It has been shown that curcumin improves oxidative stress and inhibits the expression of inflammatory cytokines, and 200mg / kg as a dose is more effective ¹⁷. After comparing the curcumin doses used in ischemia reperfusion models, the curcumin dose was applied as 200mg/kg in our study). Tissue and blood samples were taken in the period corresponding to the end of the reperfusion period.

Preparation of Therapeutic Agents

The material containing curcumin named SIGMA-ALDRICH operating in the USA was procured through the intermediary importer company by purchasing. Curcumin was dissolved using 1% dimethyl sulfoxide (DMSO) and prepared for intraperitoneal injection.

Ischemia-Reperfusion Injury Model

Ketamine 87 mg/kg intraperitoneally (Ketalar; Parke Davis, Eczacibasi, Istanbul, Turkey) and Xylazine 13 mg/kg (Rompun; Bayer AG, Leverkusen, Germany) were administered to all rats used in the experiment after 8 hours of fasting. When necessary, an additional dose was planned for once during the experiment. Midline laparotomy was performed on rats whose skin was prepared aseptically. After removing the intestines with wet gauze, the infrarenal abdominal aorta (IAA) was carefully explored. The IAA was put under a non-traumatic microvascular clamp. The microvascular clamp on the IAA was removed after 60 minutes, and 60 minutes of reperfusion was achieved. Aortic ischemia; aortic reperfusion with loss of pulsation in the distal aorta during the clamping procedure; confirmed by testing the restoration of pulsation in the distal aorta after clamp removal. In the control group, laparotomy and abdominal aortic dissection were performed in equal time (I / R time = 120 minutes), but I / R was not created in this group. To minimize the loss of heat and fluid from the peritoneal cavity during I / R periods; after the clamps were placed in the IAA and removed, saline was applied to the peritoneal cavity and the abdominal incision was temporarily covered with wet gauze. At the end of the reperfusion period, in all rats, the median laparotomy incision was opened in the mediastinum by moving upwards, the heart was reached, and blood was taken from the right ventricular cavity with the help of a 5-cc syringe. Subsequently, a right gastrocnemius abdominal aorta sample was taken. Abdominal aortic samples were stored in 10% formaldehyde solution until evaluation of immunohistochemical and hematoxylin-eosin. Blood taken from rats was centrifuged at 4000 rpm for 10 minutes and rat plasma samples were stored at -20 degrees until biochemical analysis.

Histopathological Examination of Vascular Endothelial Structure

For histopathological examination, aortic tissues were separately fixed in 10% buffered neutral formaldehyde solution. The samples were embedded in paraffin blocks. The 5-micron meter parts were taken. It was stained with hematoxylin eosin dye. A magnification of 20 objectives was used. (Olympus BX51 TF, USA) Interstitial edema, inflammatory cell infiltration and necrosis were evaluated as histopathological parameters. Ranking scores were organized and reported (No: 0, Yes: 1, Significant: 2) for each histopathological parameter. By summing all parameter scores for each sample, the histological score was calculated.

Total Antioxidant Capacity (TAC)

TAC level of the samples was measured using Rel Assay brand commercial kits. The measurement method was applied on the basis that all antioxidant molecules in the sample reduce the colored ABTS cationic radical and decolorize the colored radical in proportion to the total concentrations of the antioxidant molecules. Trolox, a water-soluble analog of vitamin E, was used as the calibrator. Results were expressed in mmol Trolox Equivalent / L¹⁸. Micromolar (μmol) changed when calculating trolox equivalent per liter.

Total Oxidant Status (TOS)

TOS of the samples were measured using Rel Assay brand commercial kits. The measurement was made using the colorimetric method, which is based on the cumulative oxidation of ferrous ion to ferric ion of the oxidant molecules contained in the samples, as stated in the working principle of the test. Results were expressed as $\mu\text{mol H}_2\text{O}_2$ Equivalent / L¹⁹.

Oxidative Stress Index (OSI) Calculation

While calculating the OSI values of the samples, TAC values were multiplied by 10 and equaled with TOS in units. The ratio of TOS levels included in the samples to TAC levels included in the samples was specified as OSI¹⁹. Results are expressed as Arbitrary Units (AU).

(TOS, $\mu\text{mol H}_2\text{O}_2$ Equiv. / L.)

OSI = _____

(TAC, $\mu\text{mol trolox Equiv. / L.}$)

Statistical Analysis

Statistical Analysis SPSS 11.5 (SPSS for Windows 11.5, Chicago, IL) package program was used for statistical evaluation. Kruskal Wallis test was used to evaluate quantitative data between groups. Group parameters were expressed as mean \pm standard deviation. Mann-Whitney U test was used again for the groups that were found to be significant. In all tests, $p < 0.05$ values were considered statistically significant.

RESULTS

The procedure was completed by all subjects. The values of TAC, TOS and OSI in blood samples taken from rats were calculated. The results were statistically compared between the groups (Table-1). The scores obtained as a result of histopathological evaluations made by an expert pathologist were compared statistically.

Comparison of TAC Values

When the mean TAC values were calculated in the plasma samples, it was seen that the lowest value was in the Curcumin group (1.10 ± 0.09 mmol Trolox Equivalent / L). The mean highest TAC value was found in the control group (1.39 ± 0.17 mmol Trolox Equivalent / L) (Table-1). TAC values of the control group were found to be statistically significantly higher than the other groups ($p < 0.05$) (Figure-2).

Comparison of TOS Values

When the mean TOS values were calculated in plasma samples, it was seen that the lowest value was ($77.11 \pm 10.08a$ $\mu\text{molH}_2\text{O}_2\text{Eqv. / L}$) in the Sham group. The mean highest TOS value was detected in the control group ($150.16 \pm 33.96b$ $\mu\text{mol H}_2\text{O}_2\text{Eqv./L}$) (Table-1). Similar to TAC results, control group TOS values were statistically significantly higher than other groups ($p < 0.05$). The Fake and Curcumin TOS values were statistically lower than those of the control group ($p < 0.05$) (Figure-3).

The OSI Values Comparison

The lowest value was seen in the Sham group ($5.22 \pm 0.36a$ AU) when average OSI values were measured for plasma samples. In the control group ($10.63 \pm 0.90b$ AU), the mean maximum OSI value was observed. (Table-1). Similar to the findings of TAC and TOS, OSI values were statistically lower in the Sham and Curcumin groups than in the control group ($p < 0.05$). Low OSI levels were observed more prominently in the Sham group ($p < 0.05$) (Figure-4).

DISCUSSION

Today, abdominal aortic clamping, which is used in cardiovascular surgery operations, is frequently used. Although vascular clamping provides surgeons with many working advantages, when the clamping area is examined, swelling, flattening, loss of intercellular connectivity and endothelial cell peeling are observed in the endothelial cells^{20,21}. At the same time, it causes damage to the vascular endothelium and tissues with the ischemia it creates and the subsequent reperfusion.

Ischemia reperfusion injury is based on free oxygen radicals that emerge as a result of tissue oxygenation during reperfusion. Necrotic changes due to the formation of free oxygen radicals can be seen in the reperfusion tissue. Reactive oxy radicals can be released from many sources. The most important are the activated neutrophils. In addition, cytokines (IL-6; IL-8; TNF), platelet activating factor, and leukotrienes, which are plasma pro-inflammatory agents, also cause endothelial cell damage to the complementary factors. Pulmonary vasoconstriction, hypertension, and increased pulmonary vascular permeability are the most common side effects of impaired endothelial cell function^{22,23}. Endothelial cells play a vital and dynamic role in maintaining vascular hemostasis (current, selective permeability and cell traffic). These cells are very sensitive

for both ischemia and reperfusion. Prolonged hypoxia causes intracellular volume increase and cytoskeletal organization disorders with cell membrane potential changes, ion distribution disorders and decrease in viscosity²⁴. With tissue reperfusion, ischemic endothelial changes become evident and endothelial dysfunction develops localized in the I / R area. Morphological changes following prolonged ischemia and subsequent reperfusion are cellular swelling, membrane depolarization, pinocytotic vesicle loss, endothelial cell basement membrane separation, and adhesion of activated leukocytes (especially neutrophils) to the endothelial cell surface^{24,25}. The primary indicator of I / R injury in arterioles is impairment and hyperreactivity in endothelium-dependent vasodilation. It was observed that endothelium-dependent arteriolar vasodilation disappeared in the early period and smooth muscle function in the late period after ischemia-reperfusion injury. Therefore, reperfusion of tissues is difficult in prolonged ischemia^{25,26}. The arteriolar I/R response varies from tissue to tissue as well. The clinical reflection of I / R damage in the arterial capillary endothelium is in the form of increased fluid filtration to the interstitial tissue and a decrease in the number of capillaries that provide tissue perfusion²⁶. Increased interstitial fluid filtration is due to an increase in endothelial barrier hydraulic permeability rather than an increase in intracapillary pressure. After tissue reperfusion, the decrease in arterial capillaries due to obstruction causes an increase in I-R damage by further disrupting tissue perfusion. Microvascular dysfunction mechanisms occur on the basis of leukocyte-endothelial adhesion. Leukocyte-derived ROS also contributes to this dysfunction. Therefore, prevention of leukocyte-endothelial adhesion and antioxidant treatment can reduce microvascular dysfunction²⁷.

Curcumin is a cardioprotective antioxidant that has lipid-lowering properties and reduces oxidative stress^{10,28-30}. Curcumin also has a protective effect on endothelial dysfunction³¹. In several ways, curcumin demonstrates its endothelial protective effect. Decreased NO bioavailability or decreased NO synthesis increases endothelial dysfunction. Curcumin decreases endothelial dysfunction by upregulating eNOS during the phase in which oxidative stress is induced¹⁶. In addition, it decreases vascular superoxide anion production and enhances this effect by inhibiting vascular protein kinase C (PKC- β)³¹. It also functions as a TNF- α blocker through the Nrf-2 / Heme oxygenase-1 (HO-1) pathway. Thus, by inhibiting oxidative stress and inflammatory cytokines, it reduces the ROS load and inflammatory damage in the vascular endothelium^{32,33}. With all these mechanisms, Curcumin protects the vascular endothelium and reduces the remodeling that occurs in the endothelium.

In this study, it has been shown that with curcumin therapy, oxidative and vascular endothelial cell harm induced by infrarenal abdominal aorta clamping can be covered. Systemic oxidative stress that occurs during ischemia and subsequent phases of reperfusion has been minimized through cross-clamping with curcumin. The fact that the TAC, TOS and OSI values in the group given curcumin were significantly lower than the control group confirms this. Although TAC, TOS and OSI values differed between the groups, two reasons were attributed to the lack of histopathological changes in the abdominal aortic tissue. The first explanation was deemed to be that the I/R duration was not long enough. It was reported in some of the studies that this time was determined to be 120 minutes for I/R³⁴. The second reason is that it is assumed that abdominal aortic tissue (due to variations in perfusion) is more resistant than other tissues to I/R injury.

Many studies have been conducted on the protective effects of curcumin. I / R injury models have been investigated in a wide variety of organ systems (heart, kidney, lung, intestine, mesentery, liver, skeletal muscle) in rats³⁵⁻³⁸. In the literature, ischemia reperfusion studies directed towards the aorta are extremely limited. Therefore, this study gives an idea about the sensitivity of the abdominal aorta to ischemia / reperfusion and to what extent Curcumin can protect the vascular endothelium.

The study has several limitations. The first is that Curcumin was given intraperitoneally, and the effects of oral intake were not seen. Second, in order to support previous studies, basic biochemical parameters and histopathological samples from different tissues are not taken with TAC, TOS, OSI.

CONCLUSION

Curcumin significantly reduced oxidative stress in the abdominal aortic I / R rat model. Oxidative stress indices and cell damages occurring in the clinic can be reduced with curcumin treatment. However, in order

to use curcumin in clinical treatment, more comprehensive scientific preclinical and clinical studies are needed in the future.

Declaration of Conflicting Interests

The author(s) declared no potential conflicts of interest with respect to the research, authorship, and/or publication of this article.

Funding

This research received no specific grant from any funding agency in the public, commercial, or not-for-profit sectors.

REFERENCES:

1. Damjanov I, Linder J. Cell injury and cellular adaptations. Anderson's Pathology. Tenth Edition Volum. 2001; 1: 357-365.
2. Herbert KJ, Hickey MJ, Lepore DA, Knight KR, Morrison VA, Stewart AG. Effects of the endothelin receptor antagonist Bosentan on inshaemia/reperfusion injury in rat skeletal muscle. *Eur J Pharmacol.* 2001 Jul 13;424(1):59-67.doi: 10.1016/s0014-2999(01)01133-5.
3. L. Willoughby, P. Dark, G. Warhurst. Investigation of systemic and mesenteric inflammatory signaling and gut-derived endothelial toxicity in patients undergoing high-risk abdominal aortic surgery. *Shock.* 2011 Aug; 36(2):121-7. doi: 10.1097/SHK.0b013e3182205bbd.
4. Petrasek PF, Walker PM. A clinically relevant small-animal model of skeletal muscle ischemia- reperfusion injury. *J Invest Surg.* Jan-Feb 1994;7(1):27-38. doi: 10.3109/08941939409018280.
5. Jayaprakasha GK, Rao LJM, Sakariah K. Chemistry and biological activities of *Curcuma longa*. *Trends Food Sci Tech.* 2005; 16: 533- 48
6. Pandya U, Saini MK, Jin GF, Awasthi S, Godley BF, Awasthi YC. Dietary curcumin prevents ocular toxicity of naphthalene in rats. *Toxicol Lett.* 2000 Jun 5;115(3):195-204.doi: 10.1016/s0378-4274(00)00191-0.
7. Aggarwal B.B., Kumar A. and Bharti A.C. Anticancer potential of curcumin: Preclinical and clinical studies. *Anticancer Res.* Jan-Feb 2003;23(1A):363-98.
8. Thiyagarajan M., Sharma, S.S., Neuroprotective effect of curcumin in middle cerebral artery occlusion induced focal cerebral ischemia in rats. *Life Sciences.* 2004 Jan 9;74(8):969-85.doi: 10.1016/j.lfs.2003.06.042.
9. Abdel-Daim, M.M., Abdou, R.H. Protective Effects of Diallyl Sulfide and Curcumin Separately against Thallium-Induced Toxicity in Rats. *Cell J.* 2015 17, 379–388.Summer 2015; 17(2):379-88.doi: 10.22074/cellj.2016.3752. Epub 2015 Jul 11.
10. Mario Pulido-Moran , Jorge Moreno-Fernandez , Cesar Ramirez-Tortosa ,Mcarman Ramirez-Tortosa .Curcumin and Health. *Molecules.* 2016 Feb 25;21(3):264. doi: 10.3390/molecules21030264.
11. F Zhang , N K Altorki, J R Mestre, K Subbaramaiah, A J Dannenberg. Curcumin inhibits cyclooxygenase-2 transcription in bile acid- and phorbol estertreated human gastrointestinal epithelial cells. *Carcinogenesis.* 1999 Mar; 20(3):445-51.doi: 10.1093/carcin/20.3.445.
12. Iqbal M., Sharma S.D., Okazaki Y., Fujisawa M., Okada S. Dietary supplementation of curcumin enhances antioxidant and phase II metabolizing enzymes in ddY male mice: Possible role in protection against chemical carcinogenesis and toxicity. *Pharmacol. Toxicol.* 2003 Jan;92(1):33-8.doi: 10.1034/j.1600-0773.2003.920106.x.
13. Robinson T.P., Ehlers T., Hubbard I.R., Bai X., Arbiser J.L., Goldsmith D.J., et al. Design, synthesis, and biological evaluation of angiogenesis inhibitors: aromatic enone and dienone analogues of curcumin. *Bioorganic and Medicinal Chemistry Letters.* 2003 Jan 6;13(1):115-7.doi: 10.1016/s0960-894x(02)00832-6.
14. Mirzabeigi, P.; Mohammadpour, A.H.; Salarifar, M.; Gholami, K.; Mojtahedzadeh, M.; Javadi, M.R. The Effect of Curcumin on some of Traditional and Non-traditional Cardiovascular Risk Factors: A Pilot Randomized, Double-blind, Placebo-controlled Trial. *Iran. J. Pharm. Res. IJPR.* Spring

- 2015;14(2):479-86.
15. Brouet I, Ohshima H. Curcumin, an anti-tumour promoter and anti-inflammatory agent, inhibits induction of nitric oxide synthase in activated macrophages. *Biochem Biophys Res Commun.* 1995 Jan 17;206(2):533-40.doi: 10.1006/bbrc.1995.1076.
 16. Boonla O., Kukongviriyapan U., Pakdeechote P., Kukongviriyapan V., Pannangpetch P., Prachaney P., et al. Curcumin improves endothelial dysfunction and vascular remodeling in 2K-1C hypertensive rats by raising nitric oxide availability and reducing oxidative stress. *Nitric Oxide.* 2014 Nov 15;42:44-53.doi: 10.1016/j.niox.2014.09.001. Epub 2014 Sep 4.
 17. Sun J, Guo W, Ben Y, Jiang J, Tan C, Xu Z, et al. Preventive effects of curcumin and dexamethasone on lung transplantation-associated lung injury in rats. *Crit Care Med.* 2008 Apr;36(4):1205-13. doi: 10.1097/CCM.0b013e31816a06fc.
 18. Erel O. A novel automated method to measure total antioxidant response against potent free radical reactions. *Clin Biochem.* 2004 Feb;37(2):112-9.doi: 10.1016/j.clinbiochem.2003.10.014.
 19. O. Erel. A new automated colorimetric method for measuring total oxidant status. *Clin. Biochem.* 2005 Dec;38(12):1103-11.doi: 10.1016/j.clinbiochem.2005.08.008. Epub 2005 Oct 7.
 20. Gertz SD, Rennels ML, Forbes MS, Kawamura J, Sunaga T, Nelson E. Endothelial cell damage by temporary arterial occlusion with surgical clips. Study of the clip site by scanning and transmission electron microscopy. *J. Neurosurg.* 1976 Nov;45(5):514-9.doi: 10.3171/jns.1976.45.5.0514.
 21. Martin Zammert , Simon Gelman. The pathophysiology of aortic cross-clamping. *Best Pract Res Clin Anaesthesiol.* 2016 Sep; 30(3):257-69. doi: 10.1016/j.bpa.2016.07.006. Epub 2016 Aug 1.
 22. M.M. Yassin, D.W. Harkin, A.A. Barros D'Sa, M.I. Halliday, B.J. Rowlands. Lower limb ischemia-reperfusion injury triggers a systemic inflammatory response and multiple organ dysfunction. *World J. Surg.* 2002 Jan;26(1):115-21.doi: 10.1007/s00268-001-0169-2. Epub 2001 Oct 25.
 23. D.W. Harkin, A.A. Barros D'sa, K. Mccallion, M. Hoper, M.I. Halliday, et al. Circulating neutrophil priming and systemic inflammation in limb ischaemia reperfusion injury. *Int. Angiol.* 2001 Mar;20(1):78-89.
 24. Carden DL, Granger DN. Pathophysiology of ischemia-reperfusion injury. *J Pathol.* 2000 Feb;190(3):255-66.
 25. Kelsall CJ, Brown MD, Hudlicka O. Alterations in reactivity of small arterioles in rat skeletal muscle as a result of chronic ischaemia. *J. Vasc. Res.* May-Jun 2001;38(3):212-8. doi: 10.1159/000051049.
 26. Seal JB, Gewertz BL. Vascular dysfunction in ischemia-reperfusion injury. *Ann Vasc Surg.* 2005 Jul; 19(4):572-84. doi: 10.1007/s10016-005-4616-7.
 27. Emili Iraculis, Angel Cequier, Joan Antoni Gómez-Hospital, Manel Sabaté, Josepa Mauri, Eduard Fernández-Nofrerias, et al. Early dysfunction and long-term improvement in endothelium-dependent vasodilation in the infarct-related artery after thrombolysis. *J. Am. Coll. Cardiol.* 2002 Jul 17;40(2):257-65.doi: 10.1016/s0735-1097(02)01953-8.
 28. Si Qin , Lifan Huang , Jiaojiao Gong , Shasha Shen , Juan Huang , Hong Ren , et al . Efficacy and safety of turmeric and curcumin in lowering blood lipid levels in patients with cardiovascular risk factors: a meta-analysis of randomized controlled trials. *Nutr J.* 2017 Oct 11;16(1):68.doi: 10.1186/s12937-017-0293-y.
 29. Han J., Pan X.Y., Xu Y., Xiao Y., An Y., Tie L., et al. Curcumin induces autophagy to protect vascular endothelial cell survival from oxidative stress damage. *Autophagy.* 2012 May 1;8(5):812-25.doi: 10.4161/auto.19471. Epub 2012 May 1.
 30. Yoona Kim , Peter Clifton. Curcumin, Cardiometabolic Health and Dementia. *Int J Environ Res Public Health.* 2018 Sep 24;15(10):2093. doi: 10.3390/ijerph15102093.
 31. Rungseesantivanon, S.; Thenchaisri, N.; Ruangvejvorachai, P.; Patumraj, S. Curcumin supplementation could improve diabetes-induced endothelial dysfunction associated with decreased vascular superoxide production and pkc inhibition. *BMC Complement Altern Med.* 2010 Oct 14;10:57. doi: 10.1186/1472-6882-10-57.
 32. Jeong G.S., Oh G.S., Pae H.-O., Jeong S.-O., Kim Y.-C., Shin M.-K., et al. Comparative effects of curcuminoids on endothelial heme oxygenase-1 expression: Ortho-methoxy groups are essential

- to enhance heme oxygenase activity and protection. *Exp. Mol. Med.* 2006 Aug 31;38(4):393-400.doi: 10.1038/emm.2006.46.
33. Anthwal A., Thakur B.K., Rawat M.S.M., Rawat D.S., Tyagi A.K., Aggarwal B.B. Synthesis, characterization and in vitro anticancer activity of C-5 curcumin analogues with potential to inhibit TNF-alpha-induced NF-kappaB activation. *BioMed Res. Int.* 2014;2014:524161.doi: 10.1155/2014/524161. Epub 2014 Jul 24.
 34. Medine C Cure , Erkan Cure , Yildiray Kalkan, Levent Tumkaya , Ibrahim Aydin , Aynur Kirbas , et al . The Protective Effect of Adalimumab on Renal Injury in a Model of Abdominal Aorta Cross-Clamping. *Adv Clin Exp Med.* Mar-Apr 2016;25(2):219-26. doi: 10.17219/acem/33250.
 35. Nurullahoglu-Atalik KE, Okudan N, Belviranli M, Gokbel H, Oz M, Esen H. Role of curcumin in mesenteric ischemia-reperfusion injury in rats. *Bratisl Lek Listy.* 2012;113(8):465-70.doi: 10.4149/bll.-2012.103.
 36. Guzel A, Kanter M, Guzel A, Yucel AF, Erbogga M. Protective effect of curcumin on acute lung injury induced by intestinal ischemia/reperfusion. *Toxicol Ind Health.* 2013 Aug;29(7):633-42.doi: 10.1177/0748233711430984. Epub 2012 Jan 17.
 37. Avci G, Kadioglu H, Sehirli AO, Bozkurt S, Gudu O, Arslan E, et al. Curcumin Protects Against Ischemia/Reperfusion Injury in Rat Skeletal Muscle. *J Surg Res.* 2012 Jan;172(1):e39-46.doi: 10.1016/j.jss.2011.08.021. Epub 2011 Sep 13.
 38. Mehmet Salih Aydin , Ahmet Caliskan , Aydemir Kocarslan , Sezen Kocarslan , Ali Yildiz , Samil Günay , et al . Intraperitoneal curcumin decreased lung, renal and heart injury in abdominal aorta ischemia/reperfusion model in rat. *Int J Surg.* 2014;12(6):601-5.doi: 10.1016/j.ijssu.2014.04.013. Epub 2014 May 9

LEGENDS

Table Legends

Table-1 : TAC, TOS, OSI measurements (Arithmetic mean \pm Standard deviation)

Figure Legends

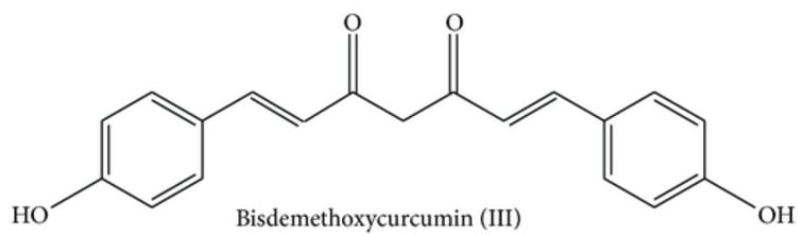
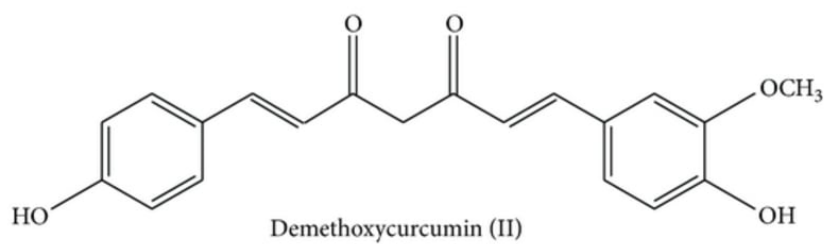
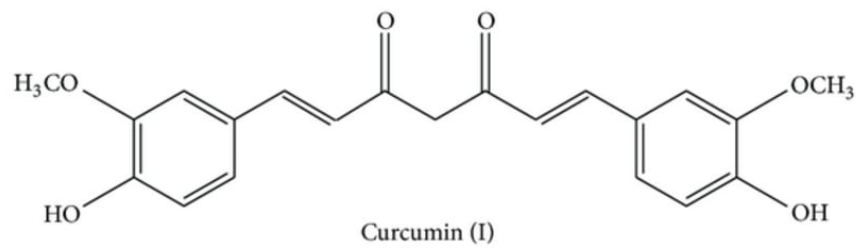
Figure- 1: Chemical structure of Curcuminoids.

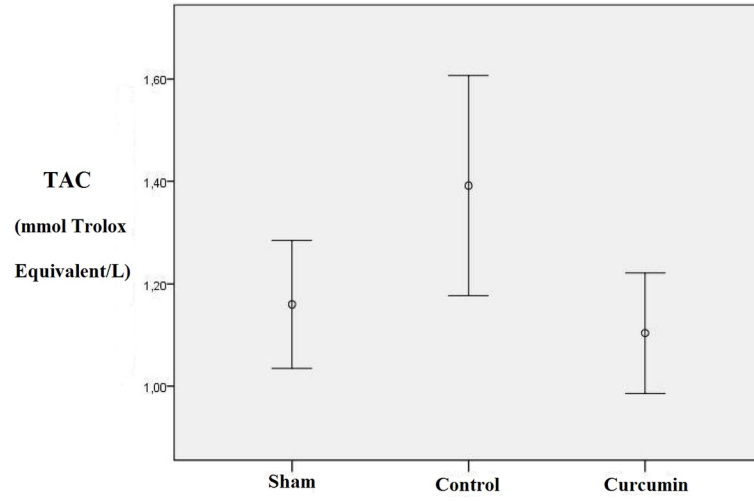
Figure- 2: Comparison of TAC (Total antioxidant capacity) values between groups.

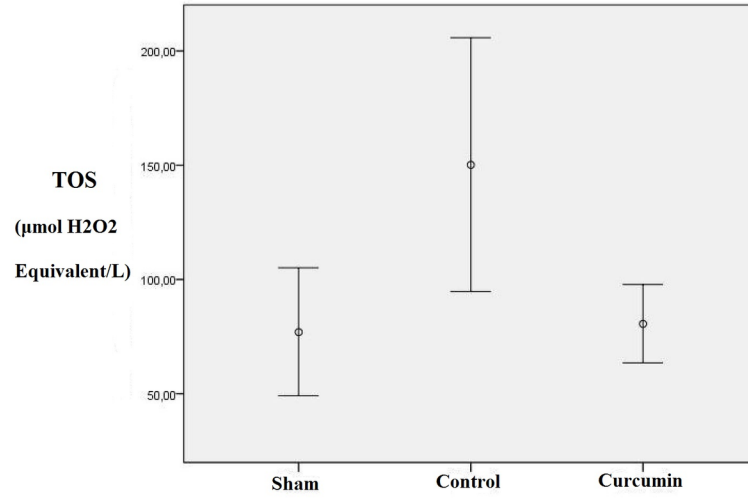
Figure- 3: Comparison of TOS (Total oxidant status) values between groups.

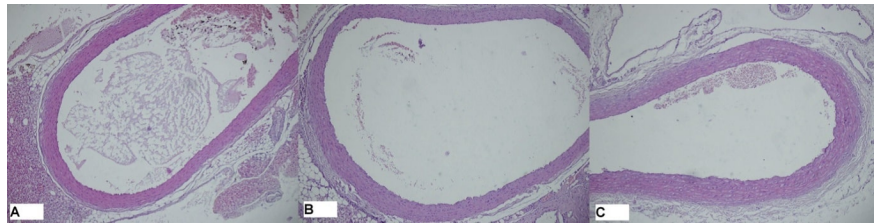
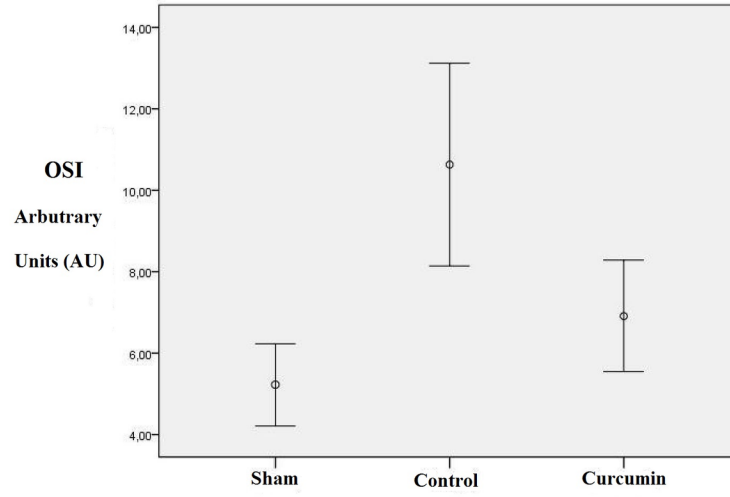
Figure- 4: Comparison of OSI (Oxidative stress index) values between groups.

Figure- 5: Aorta tissue samples of the sham, control and curcumin group. There was no histopathological difference between the groups. A = Sham group, B = Control group, C = Curcumin group.









Hosted file

Table-1.docx available at <https://authorea.com/users/727292/articles/709210-efficiency-of->

curcumin-in-preventing-ischemia-reperfusion-damage-in-aortic-vascular-endothelial-cells