

# Left Ventricle only single lead pacing in a patient with a tricuspid mechanical valve and a previous coronary sinus malfunctioning lead

Andre Grazina<sup>1</sup>, Pedro Silva Cunha<sup>1</sup>, and Mário Oliveira<sup>1</sup>

<sup>1</sup>Hospital de Santa Marta

March 07, 2024

## Abstract

Prosthetic tricuspid valves make permanent pacing challenging. We describe a case of a patient with several previous heart surgeries with a mechanical tricuspid valve and a previous malfunctioning left ventricle lead and recurrent syncope. A quadripolar lead was placed in the coronary sinus, using a specific left ventricle sensing algorithm.

## Introduction

Transvenous right ventricular (RV) endocardial lead placement is the conventional practice in clinical pacing. In some situations, as in the presence of prosthetic tricuspid valve (PTV), the inaccessibility to the RV makes the permanent pacing through a coronary sinus (CS) lead placement a good alternative. [1-2] There are also described cases of dual-site ventricular pacing through the coronary sinus to cardiac resynchronization in patients with high pacemaker dependance and lower left ventricle (LV) ejection fraction.[3-5]

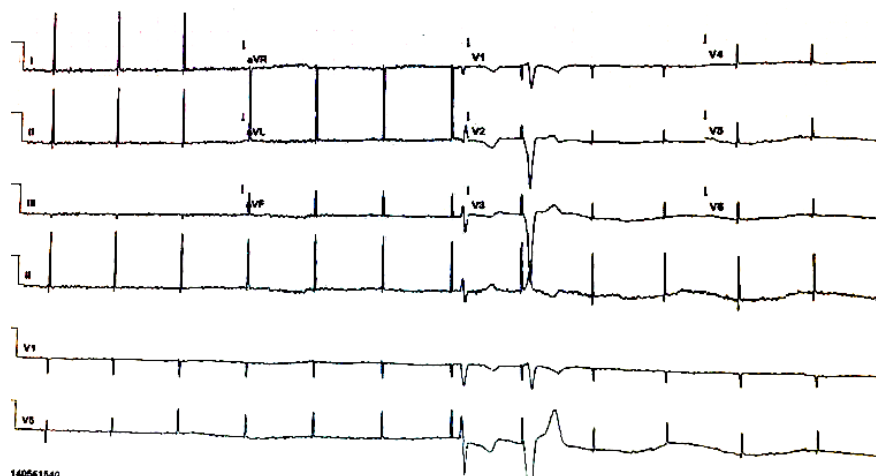
Epicardial lead implantation may be an alternative but requires invasive surgical placement, making it a less ideal option in patients with a prior thoracotomy. Regarding single ventricle pacing with a CS lead, low sensing and unacceptable threshold at implantation can be an important issue, especially when using a conventional RV pacing lead.[1-2] Quadripolar LV leads are associated with more satisfactory results as they are able to pace in several places of the LV wall, multiple vectors along the lead, allowing us to avoid suboptimal pacing sites, such as places with fibrosis.[6]

## Clinical case description

A 42 years-old patient presented, one week after a surgical valve replacement, presented in the emergency room due to episodes of syncope. The patient had a past medical history of rheumatic valvular heart disease and had been submitted to three valvular surgeries. At the first surgery (22 years before) a mitral and tricuspid valvuloplasty was performed, and 6 years later, due to progressive valvular stenosis, a mechanical prosthetic mitral valve and bioprosthetic tricuspid valve was implanted. As a consequence of the second surgery, a high degree AV block occurred, and a right infraclavicular dual-chamber pacemaker (PM) was implanted. Owing to the presence of the prosthetic tricuspid valve, the ventricular pacing lead (unipolar) was placed through the coronary sinus in the anterior vein.

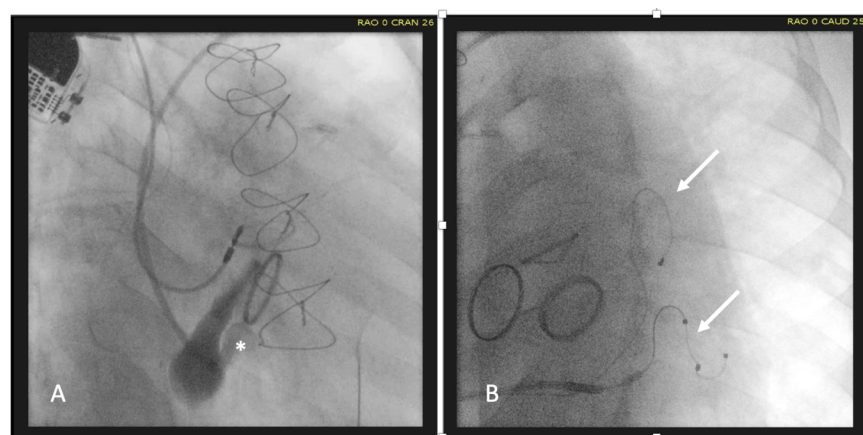
A week before the current hospital admission, the patient had a third valvular surgery. At this time, he had a replacement of the tricuspid mechanical valve and was submitted to an aortic mechanical valve implantation. The immediate post-operative period was uncomplicated. Regarding heart rhythm, the patient had previously developed a permanent Atrial Fibrillation (AF) and had the PM reprogrammed to VVI mode.

One week after discharge he had 3 episodes of syncope and recurred to the emergency department. The admission ECG revealed AF and pacing spikes without ventricular capture and prolonged ventricular asystole (figure 1).



**Figure 1.** ECG showing Atrial fibrillation with several pacing spikes without ventricular capture and significant pauses. An escape ventricular complex is seen after a non-capture pacing spike, and a subsequent ventricular pacing depolarization occurred

The device interrogation showed that the threshold was  $>5V / 0.5ms$ , and the device was programmed with an output of  $7.5V / 0.5ms$  to assure ventricular capture. The clinical case was discussed in heart team meeting, where due to the history of three previous heart surgeries with probable multiple and severe adhesions and fibrosis of mediastinum complicating the placement of an epicardial lead, it was decided to try an endocardial approach. Through a left subclavian access, the CS was cannulated with an Extended Hook sheath (Medtronic<sup>?</sup>, Attain Command) and a lateral tributary vein with a sub-selective sheath (Medtronic<sup>?</sup>, Attain Select 90s). A quadripolar lead (Medtronic<sup>?</sup>) was placed in the lateral vein of the CS (figure 2).

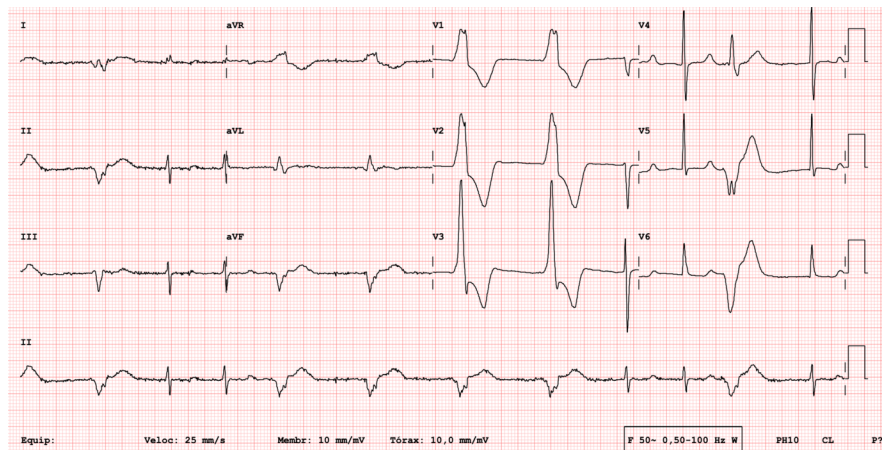


**Figure 2.** Venography of the CS (A) showing a lateral vein tributary of the CS (white asterisk) and the final image (B) showing two leads placed in the CS (two white arrows).

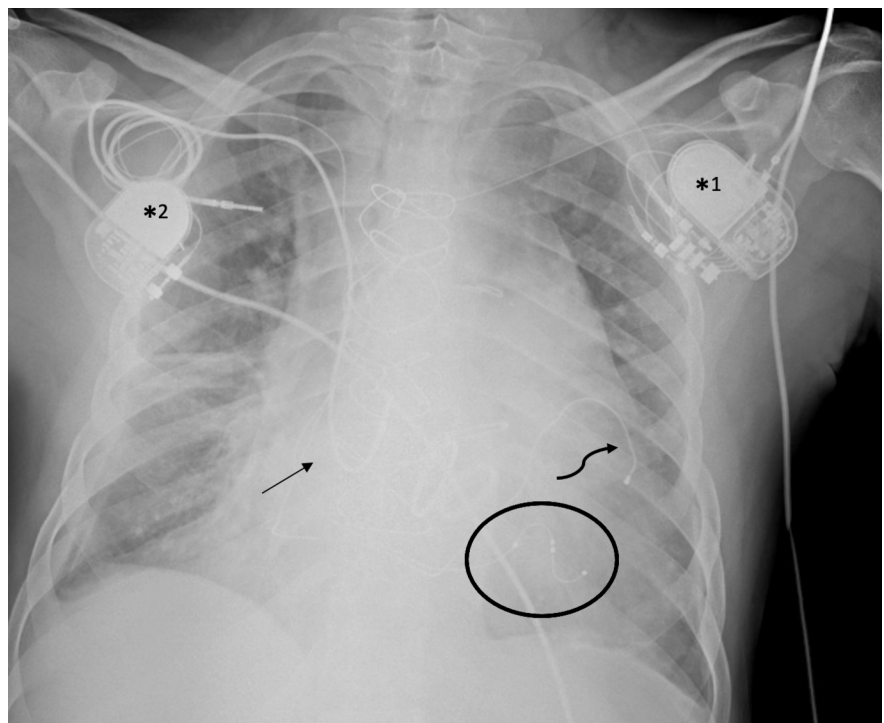
A CRT-P device (Biotronik<sup>?</sup> Enitra Hf-T Qp) was connected to the LV quadripolar lead and a plug was placed at the RV port. In this circumstance the device was programmed in VVI-BiV at 55bpm. As the device didn't have RV sensing and was programmed in LV only pacing, we used the Biotronik<sup>?</sup> LV T-wave protection algorithm as a sensing mechanism.

Post-procedural EKG (figure 3) showed AF rhythm with some periods of patient's rhythm alternating with

ventricular pacing. Notice that there is ventricular sensing, avoiding pacing on the repolarization period, but does not reset the timer to 1090ms (VVI 55bpm). Post-procedural X-ray (figure 4) showed no complications, and the patient was discharged. At 3 months, the patient was clinically well, asymptomatic, and the device interrogation revealed 63% LV pacing, with sensing 9.6mV, impedance of 3120 ohms and pacing threshold of 3.8V/ 1.25ms.



**Figure 3.** Post-procedural EKG with AF rhythm and ventricular pacing alternating with the patient's heart rhythm.



**Figure 4.** Post-procedural chest X-ray, revealing in left infraclavicular position the new-implanted CRT-P generator (asterisk 1), connected to a CS quadripolar lead (circle). It is also possible to see the right

infraclavicular single chamber pacemaker (asterisk 2) connected to the first unipolar CS lead (curved arrow) and the abandoned atrial lead (straight arrow). There is no sign of pulmonary complications.

## Discussion

The use of a single ventricular lead placed in the coronary sinus in patients with prosthetic tricuspid valves is well established.<sup>[1-5]</sup> Data shows that ventricular sensing by an LV lead placed in the coronary veins is feasible and reliable<sup>[7]</sup>. When compared to the unipolar leads, quadripolar leads have the advantage of having more pacing sites which can optimize the pacing threshold,<sup>[6]</sup> but the disadvantage of not allowing to perform conventional ventricular sensing, as it is usually achieved by the RV lead in patients with CRT-P. Among device manufacturers, Biotronik<sup>2</sup> resynchronization devices have independently RV and LV pacing and sensing. While RV sensing is used for RV-based timing and RV pacing inhibition, LV sensing is only used to prevent a pacemaker-induced arrhythmia, as it inhibits a scheduled pace event for 300 to 500ms to avoid LV pacing during the vulnerable recovery period (T wave) but does not reset the lower rate timer – this feature is referred to as LV T-wave protection.<sup>[8]</sup> Here, we describe a patient with a mechanical tricuspid valve and a previous malfunctioning CS unipolar lead that was submitted to a second lead implantation in the CS. It was decided to a quadripolar lead due to the several pacing options allowing the optimization of the pacing threshold. Due to the presence of patient's heart rhythm for periods, a Biotronik<sup>2</sup> CRT-P generator was chosen to perform LV sensing using the LV T-wave protection algorithm. The chosen endocardial approach avoided a fourth surgical intervention to place an epicardial lead, that would have been associated with increased morbidity. As far as we know, it is the first described case of a patient with prosthetic tricuspid valve and a previous CS malfunctioning lead that was submitted to a single ventricular quadripolar lead placement in the CS, programmed at VVI-BiV and using only the LV T-wave protection algorithm as sensing mechanism.

## ACKNOWLEDGMENTS

No acknowledgments to report.

## CONFLICT OF INTEREST

The authors have no conflict of interest to declare.

## AUTHOR CONTRIBUTIONS

PSC and MMO: designed and directed the project. AG and PSC: collected the data. AG: wrote the manuscript with support from PSC and MMO.

## ETHICAL APPROVAL

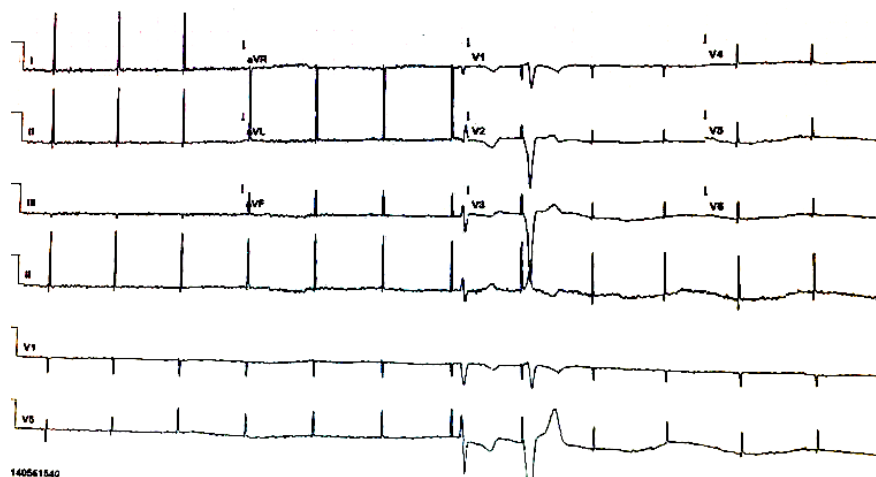
Written informed consent was obtained from the patient for the publication of this case report.

## References:

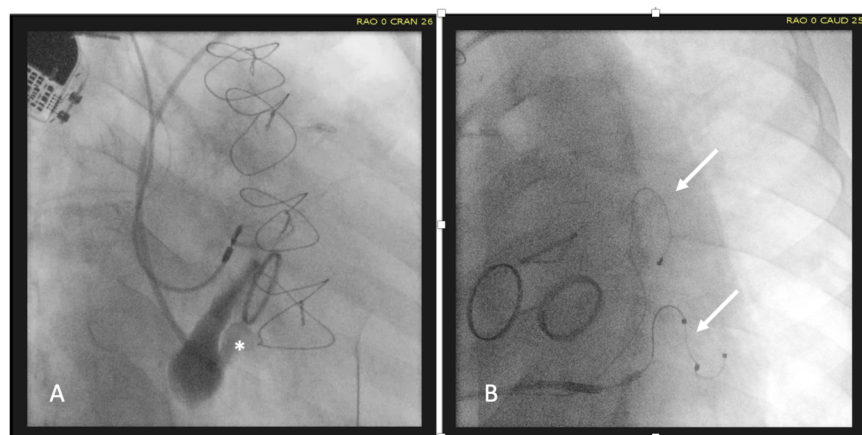- [1] Vijayakumar M, Kamath P, Pai PG. Permanent Pacing in a patient with tricuspid prosthesis – Widening therapeutic use of coronary sinus. *Indian Heart Journal* 2013; 65: 611-613
- [2] Khodor S, Mishra S, Sayad D, Kharod A. Left Ventricular Pacing in Patients with Mechanical Tricuspid Valve Replacement. *International Journal of Clinical Cardiology* 2019; 6:148
- [3] Srinivasan NT, Segal OR. Biventricular pacing and coronary sinus ICD lead implantation in a patient with a mechanical tricuspid valve replacement. *Journal of Cardiology Cases* 2015; 12:180-182
- [4] Zheng C, Lin W, Lin Y, et al. Case presentation: implantation of cardiac resynchronization therapy pacemaker via the coronary sinus in a patient with triple valve replacement. *BMC Cardiovascular disorders* 2018; 18:37
- [5] Yolcu M. Simultaneous pacing from two branches of coronary sinus in a patient with prosthetic tricuspid valve and complete heart block. *BMC Cardiovascular disorders* 2020; 20:69

- [6] Everdingen WM, Cramer MJM, Doevendans A, et al. Quadripolar Leads in Cardiac Resynchronization Therapy. *JACC: Clinical Electrophysiology* 2015; 225-237
- [7] Biffi M, Zan G, Massaro G et al. Is ventricular sensing always right, when it is left?. *Clinical Cardiology* 2018; 41(9): 1238-1245
- [8] Helm RH, Bhatt AG, Monahan KM. Failure of Cardiac Resynchronization Therapy due to Inappropriate Inhibition of Left Ventricular Pacing during Biventricular Pacing. *The Journal of Innovations in Cardiac Rhythm Management* 2015; 6(3)

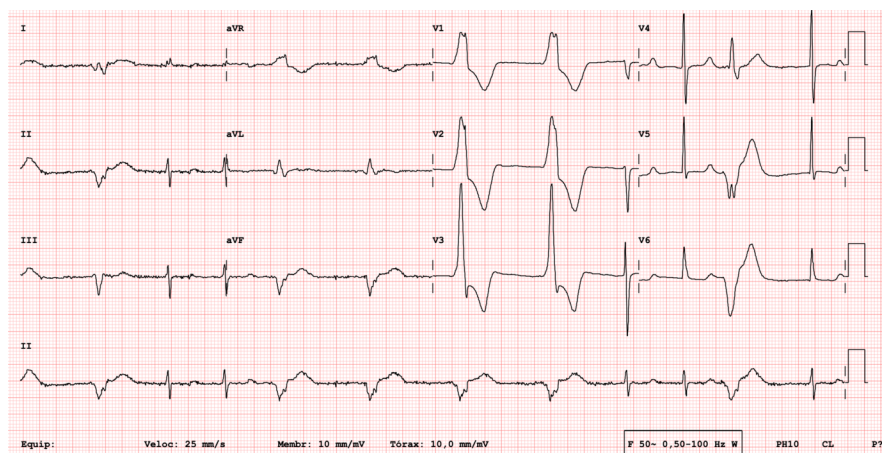
## FIGURES



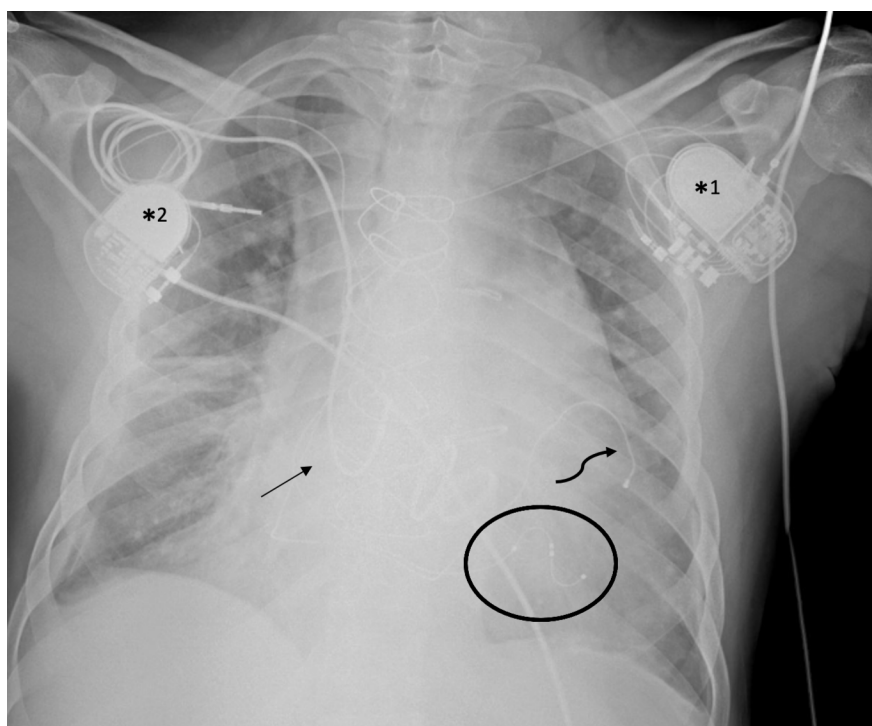
**Figure 1.** ECG showing Atrial fibrillation with several pacing spikes without ventricular capture and significant pauses. An escape ventricular complex is seen after a non-capture pacing spike, and a subsequent ventricular pacing depolarization occurred.



**Figure 2.** Venography of the CS (A) showing a lateral vein tributary of the CS (white asterisk) and the final image (B) showing two leads placed in the CS (two white arrows).



**Figure 3.** Post-procedural EKG with AF rhythm and ventricular pacing alternating with the patient's heart rhythm.



**Figure 4.** Post-procedural chest X-ray, revealing in left subclavicular position the new-implemented CRT-P generator (asterisk 1), connected to a CS quadripolar lead (circle). It is also possible to see the right infraclavicular single chamber pacemaker (asterisk 2) connected to the first unipolar CS lead (curved arrow) and the abandoned atrial lead (straight arrow). There is no sign of pulmonary complications.

