

Multidisciplinary treatment with adjunctive orthodontics, surgical crown lengthening, and esthetic rehabilitation

Viet Hoang¹, Dang Thi Nhu Thao¹, Tran Phuoc², Do Hung³, and Anand Marya⁴

¹Van Lang University

²Saigon Dental Private Hospital

³Saigon Private Dental Hospital

⁴University of Puthisastra

August 28, 2024

Multidisciplinary treatment with adjunctive orthodontics, surgical crown lengthening, and esthetic rehabilitation

Hoang Viet¹, Dang Thi Nhu Thao¹, Tran Hong Phuoc², Do The Hung³, Anand Marya⁴

1. Department of Orthodontics & Pedodontics, Faculty of Dentistry, Van Lang University, Ho Chi Minh, Viet Nam
2. Department of Oral Surgery, Sai Gon Dental Private Hospital, Ho Chi Minh, Viet Nam
3. Department of Implantology, Sai Gon Dental Private Hospital, Ho Chi Minh, Viet Nam
4. Department of Orthodontics, University of Puthisastra, Phnom Penh, Cambodia.

Corresponding Author:

Professor Anand Marya,
Department of Orthodontics,
Faculty of Dentistry,
University of Puthisastra,
Phnom Penh,
Cambodia.

Email: amarya@puthisastra@edu.kh

Abstract: Anterior spacing caused by missing upper lateral incisors and edge-to-edge position in the front teeth can negatively affect the appearance of a person's smile, leading to mental and social distress. A 29-year-old woman approached with the issue of edge-to-edge anterior occlusion, upper and lower spacing, missing lateral teeth, and improper occlusion. The treatment plan involved an interdisciplinary approach with orthodontics, implants, periodontics, and prosthodontics. After orthodontic treatment, third molar extraction and two buccal shelf mini screws were recommended to distalize the lower posterior teeth and retract the lower incisors using a power chain. Gingivoplasty and veneer restorations were performed on teeth 14 to 24 to improve the patient's smile aesthetics. The interdisciplinary approach used in this case involved fixed orthodontics, periodontal surgery, and prosthodontics to manage and improve the patient's smile and facial appearance.

Key clinical Message: Multidisciplinary orthodontic treatment is a collaborative approach involving various dental and medical specialties to address complex dental and craniofacial issues. This approach is particularly beneficial in cases involving: Severe malocclusions, congenitally missing teeth, periodontal disease, facial deformities, extensive restorative needs.

Keywords: Class III, mini-screws, prosthodontics, implant, gingivoplasty.

Introduction

In modern dental practice, achieving optimal esthetic and functional outcomes often necessitates a multidisciplinary approach. This involves the integration of various dental specialties to address complex dental issues comprehensively. One such approach includes the combination of adjunctive orthodontics, surgical crown lengthening, and esthetic rehabilitation. Multidisciplinary orthodontic treatment is a collaborative approach involving various dental and medical specialties to address complex dental and craniofacial issues. This integrated treatment plan ensures comprehensive care, optimizing both esthetic and functional outcomes for patients with multifaceted dental needs. Orthodontic treatment alone can correct many issues related to tooth alignment and occlusion. However, when combined with other dental specialties, it can significantly enhance overall dental health and aesthetics. This approach is particularly beneficial in cases involving: Severe malocclusions, congenitally missing teeth, periodontal disease, facial deformities, extensive restorative needs. Smiling has a significant impact on the satisfaction of individuals, it is related to skeletal, dental, and soft-tissue problems [1]. In some patients, the absence of upper lateral incisors and an edge-to-edge position in the anterior region of the mouth can impact the aesthetics of their smile. This can cause mental and social trauma. Before initiating any treatment, it is important to carefully consider the underlying cause of these diastemas. Individualized treatment planning is necessary for such cases, which may involve more than just fixed orthodontic treatment. Successful outcomes may require a combination of periodontal [2,3,4,5,6], surgical, and prosthodontic treatments [7].

Case presentation:

Diagnosis and etiology

The patient is a 29-year-old woman who came to the clinic with several chief complaints including an anterior spacing, gummy smile and missing teeth. During clinical examination, we found the patient had edge-to-edge anterior occlusion, upper and lower spacing, missing lateral teeth and non-stable occlusion. She has a concave profile; no symptoms of temporomandibular disorders were detected. Upon examination, it was found that the patient had a Class III molar and canine relationship on both sides. She also had the agenesis of maxillary right lateral incisor, a small left lateral incisor, spacing on upper and lower, and normal Curve of Spee. The right missing lateral incisor and small left lateral incisors created Bolton tooth size discrepancy. The upper and lower midline coincided with the facial midline. The gingival biotype was thin-scalloped. The upper anterior teeth crowns were short. The lateral cephalometric analysis showed a skeletal Class III tendency jaw relationship with slightly more protruded placed mandibular than maxilla (SNA, 86.2°; SNB, 86°; ANB, 0.2°), and normal lower facial height (FMA, 28°). The upper incisors were normal and mandibular incisors were retroclined (U1-SN, 111.7°; L1-MP, 84,7). The upper lip was behind the E line and lower lip was in front of the E-line. The panoramic radiograph confirmed the right missing maxillary lateral incisor, the others of teeth were present. [Figure 1,2].

Clinical findings:

Soft tissue:

- Concave profile
- Acute nasolabial angle
- Strain on circumoral muscle when closing mouth (no TMJ symptoms)

Dental:

- Molar relationship: Class III

- Canine relationship: Class III
- Reverse upper smile arch
- Archform:
- Upper: Normal
- Lower: Normal
-
- Upper arch:
- 10mm spacing.
- Missing 12 teeth.
- Small 22 teeth
- Lower arch:
- 3mm spacing.
- Normal curve of Spee
- Bolton discrepancy: Abnormal because of missing teeth
- Midline: upper and lower coincident with facial midline

Skeletal:

- Skeletal jaw relationship: class III tendency (ANB 0.2°)
- Maxilla and mandible: Protruded position (SNA 86.2°, SNB 86°)
- Lower facial height: normal (FMA 28°)
- Incisor angulation
- Upper: Normal (U1-SN 111.7°)
- Lower: Retroclined (L1-MP 84.7°)

Diagnostic Assessment

Lip position assessment:

- Upper and lower lips protrusive
- Both lips anterior to E-line
- Hypermobility lip
- Smile: Gummy smile 1 mm
- Buccal corridors: Normal

Dental assessment

- Molar relation: Class III
- Canine relation: Class III
- Arch form:
- Upper: Normal with severe spacing
- Lower: Normal with mild spacing
- Dental discrepancy: Abnormal Bolton tooth size discrepancies
- Incisor angulation:
- Mandibular incisors retrocline

Skeletal:

Class III tendency jaw relationship

Normal lower facial height.

Treatment objectives

- Eliminate the anterior spacing.
- Achieving satisfactory smile aesthetics and masticatory function.
- Stable occlusion and treatment outcome in long term.

Potential alternative treatments

In discussions with the patient regarding this case, we presented several treatment options, including the choice between the current treatment plan and treatment combined orthodontic and orthognathic surgery treatment with lefort I on the maxillary and BSSO on the mandibular because of the skeletal discrepancies. However, the patient refused the surgery option because of the cost and scaring of the surgery.

Treatment Timeline:

- 1st Stage: Orthodontic treatment with fixed appliance, 4 wisdom teeth extraction and implant installation for 12 teeth
- 2nd Stage: Gingivoplasty after 2 weeks of debonding
- 3rd Stage: Prosthodontic treatment

Treatment progress:

The patient underwent an interdisciplinary treatment plan involving orthodontics, implants, periodontics, and prosthodontics. The treatment was conducted in three stages.

- In the first stage, orthodontic treatment was administered. 3D simulation was done to predict the mechanic and consult with the patient before treatment. [Figure 3] The dentist recommended the extraction of wisdom teeth and the use of two buccal shelf mini screws to distalize the lower posterior teeth and retract the lower incisors. The upper incisors were proclined, and the lower incisors were retroclined slightly to achieve good overjet and overbite. Normally, we use this way for class III camouflage treatment [8]. The upper wire made the smile arch back to normal position instead of reverse smile arch before. The orthodontic treatment created space for the installation of an implant in the 12th tooth position. Implant placement was done during the orthodontic treatment, and a temporary crown was placed. After the orthodontic treatment, the spaces in the upper anterior were redistributed, and veneer restorations were carried out. [Figure 4,5,6,7,8,9]

- In the second stage, gingivoplasty was performed two weeks after the completion of the orthodontic treatment. Gummy smile 4mm appeared after the first stage because the reverse smile arch was treated. After treatment, a beautiful smile arch was designed. [Figure 12]

- In the third stage, prosthodontic treatment was administered, involving veneer and crown restorations from 14 to 24 to improve the patient's smile aesthetics. The prosthodontic treatment was carried out after one month of gingivoplasty treatment. [Figure 13]

Treatment results:

All treatment objectives were successfully achieved, resulting in a well-aligned upper and lower arch, and improved facial aesthetics. The post-treatment pictures, X-rays, superimposition, and cephalometric analysis demonstrated the outcomes. The upper incisors were slightly tilted forward by 2 degrees, while the lower incisors were moved backwards using buccal shelf mini screws, correcting the edge-to-edge position. A Class I canine relationship was achieved on both sides, and all spaces between the teeth were closed. Good root parallelism with minimal root resorption was achieved during the treatment. Cephalometric superimposition showed an improvement in overbite, overjet, and soft tissue profile, particularly in E-line and nasolabial angle. These changes were confirmed by the cephalometric analysis, showing an increase in the inclination of maxillary incisors by 2° and a decrease in the inclination of mandibular incisors by 12°. After treatment, the IMPA was only 72.2, and long-term follow-up is needed to ensure stability. Additionally, the gingivoplasty, implant installation, and all restorations after treatment were successful, resulting in a beautiful smile for the patient. After 3 months of follow-up, the patient returned for a checkup, and everything is stable and satisfactory. [Figure 10, 11, 14, 15, 16, 17, Table 1]

Discussion:

The evolution of dental care has increasingly leaned towards a multidisciplinary approach, recognizing that complex dental problems often require the combined expertise of various specialties. Multidisciplinary ortho-

dontic treatment exemplifies this trend, involving orthodontists, periodontists, prosthodontists, oral surgeons, pediatric dentists, and aesthetic dentists working together to provide comprehensive care. This collaboration is essential for addressing intricate cases that a single specialist might not effectively manage alone.

Many treatment options are available to patients for space closure and improving their smile. Restorations and implants are some of the commonly used options that can significantly enhance the patient's smile. These cost-effective techniques can be done in fewer appointments than other options, making them a popular choice. Dentists have utilized multidisciplinary approaches to ensure better esthetic results than those obtained with singular approaches. In this case, orthodontic treatment is required for long term results. The patient's profile was completely altered after the first stage, but the outcome will be improved with orthognathic surgery, particularly in borderline cases like this [9]. However, in contrast, multidisciplinary approaches had some disadvantages such as:

- **Coordination and Communication:** One of the primary challenges in multidisciplinary treatment is ensuring effective communication and coordination among different specialists. Regular interdisciplinary meetings and detailed treatment plans are essential for synchronizing efforts and avoiding conflicting treatments.
- **Patient Compliance:** Multidisciplinary treatments often require longer time frames and multiple appointments, which can be challenging for patient compliance. Clear communication about the benefits and necessity of each step, along with patient education and motivation strategies, can improve adherence to the treatment plan.
- **Cost Considerations:** Multidisciplinary treatment can be more costly due to the involvement of multiple specialists and extended treatment duration. Transparent discussions about costs, insurance coverage, and payment plans can help manage patient expectations and financial planning.
- **Technological Integration:** Integrating various technologies and treatment modalities requires seamless collaboration and sometimes advanced training. Ensuring all team members are proficient in using shared technologies, such as digital imaging systems and electronic health records, can facilitate smoother coordination.

Conclusion:

The combined approach of adjunctive orthodontics, surgical crown lengthening, and esthetic rehabilitation represents the pinnacle of modern dental care. By integrating these specialized techniques, dental practitioners can comprehensively address complex dental issues, ensuring both functional and aesthetic excellence. In conclusion, the multidisciplinary treatment [10] involving adjunctive orthodontics, surgical crown lengthening, and esthetic rehabilitation is a robust and effective strategy for managing comprehensive dental issues. This approach not only enhances the immediate appearance and function of the teeth but also contributes to long-term oral health and patient satisfaction. By leveraging the strengths of various dental specialties, practitioners can deliver superior care that meets the highest standards of modern dentistry.

Data Availability

The data that support the findings of this study are available from the corresponding author upon reasonable request.

Author Contribution

Hoang Viet: Conceptualization; data curation; resources; software; writing – original draft; writing – review and editing. **Tran Hong Phuoc:** Conceptualization; resources; software; supervision; writing – original draft; writing – review and editing. **Dang Thi Nhu Thao:** Conceptualization; resources; software; visualization; writing – original draft; writing – review and editing. **Do The Hung :** Conceptualization; resources; software; visualization; writing – original draft; writing – review and editing. **Anand Marya:** Conceptualization; formal analysis; supervision; writing – original draft; writing – review and editing.

Patient Consent

Written informed consent was obtained from the patient to publish this report in accordance with the journal's patient consent policy.

References:

1. De Oliveira AT, Paes-Souza SA, Garcia MA, Mattos CT, Nojima MC. Therapeutic effects of botulinum toxin type A in subjects with gummy smile: A longitudinal sEMG approach. *Int Orthod* 2021; 19:652-8.
2. Liudvikas Planciunas, Alina Puriene, Grazina Mackeviciene. Surgical lengthening of the clinical tooth crown. *Stomatologija, Baltic Dental and Maxillofacial Journal*, 8:88-95, 2006
3. Joanne Cunliffe, Nick Grey. Crown Lengthening Surgery –Indications and Techniques. *Dent Update* 2008 Jan-Feb;35(1):29-30, 32, 34-5
4. Gerardo Mendoza-Azpur, DDS, MSc, Heydi Cornejo, DDS, Milton Villanueva, DDS, Renato Alva, DDS, and André Barbisan de Souza, DDS, MSc. Periodontal plastic surgery for esthetic crown lengthening by using data merging and a CAD-CAM surgical guide. *J Prosthet Dent* 2020. 5. ArunA Nautiyal, SheelA Gujjari, Vikas Kumar. Aesthetic Crown Lengthening Using Chu Aesthetic Gauges and Evaluation of Biologic Width Healing. *Journal of Clinical and Diagnostic Research*. 2016 Jan, Vol-10(1): ZC51-ZC55
6. Coachman C, Valavanis K, Silveira FC, et al. The crown lengthening double guide and the digital Perio analysis. *J Esthet Restor Dent*. 2022;1-7.
7. Sampaio CS, Tonolli G, Marin G, Atria PJ. Multidisciplinary clinical approach of an orthodontic treatment and complete digital rehabilitation of laminate veneers for esthetically compromised worn teeth. *Int J Comput Dent*. 2021 Jun 4;24(2):181-194. PMID: 34085503.
8. Ngan P, Moon W. Evolution of Class III treatment in orthodontics. *Am J Orthod Dentofacial Orthop*. 2015 Jul;148(1):22-36. doi: 10.1016/j.ajodo.2015.04.012. PMID: 26124025.
9. Reis GM, de Freitas DS, Oliveira RC, de Oliveira RCG, Pinzan-Vercelino CRM, Freitas KMS, Valarelli FP. Smile attractiveness in class III patients after orthodontic camouflage or orthognathic surgery. *Clin Oral Investig*. 2021 Dec;25(12):6791-6797. doi: 10.1007/s00784021-03966-w. Epub 2021 May 6. PMID: 33959816.
10. Viet H, Phuoc TH, Tuyen HM, Marya A. Use of surgical grafting as a part of multidisciplinary treatment for a patient treated with fixed orthodontic therapy to improve treatment outcomes. *Clin Case Rep*. 2023 Dec 29;12(1): e8386. doi: 10.1002/ccr3.8386. PMID: 38161646; PMCID: PMC10756947

Figure 1: Pre-treatment intraoral and extra oral pictures

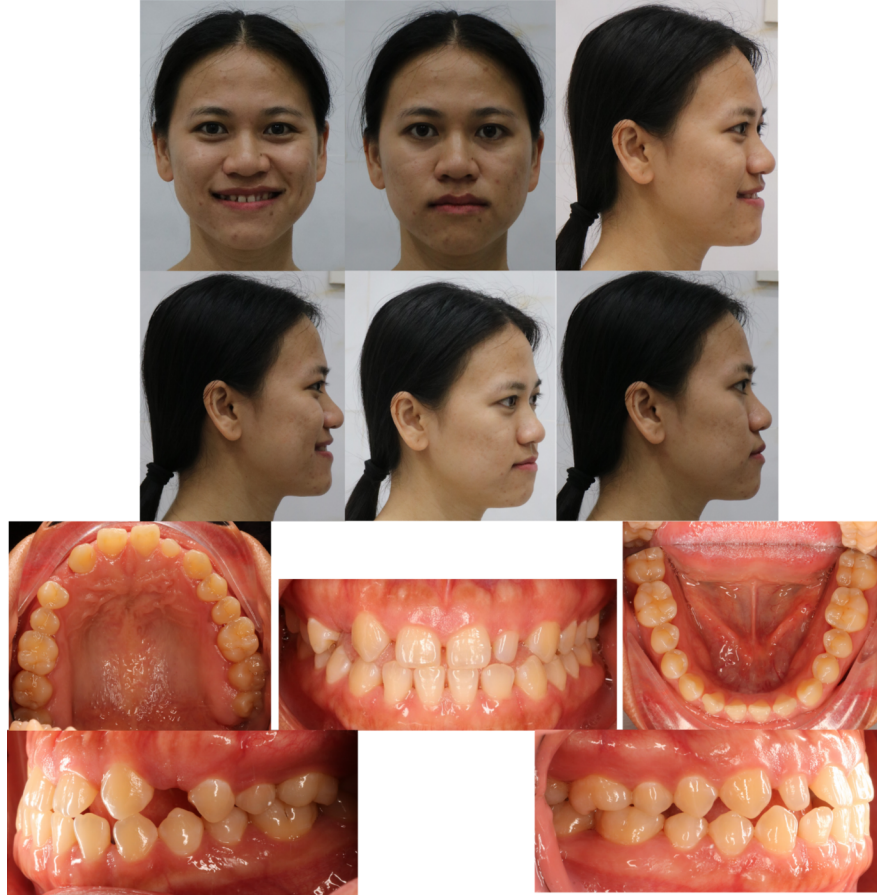

Figure 2: Initial X rays records

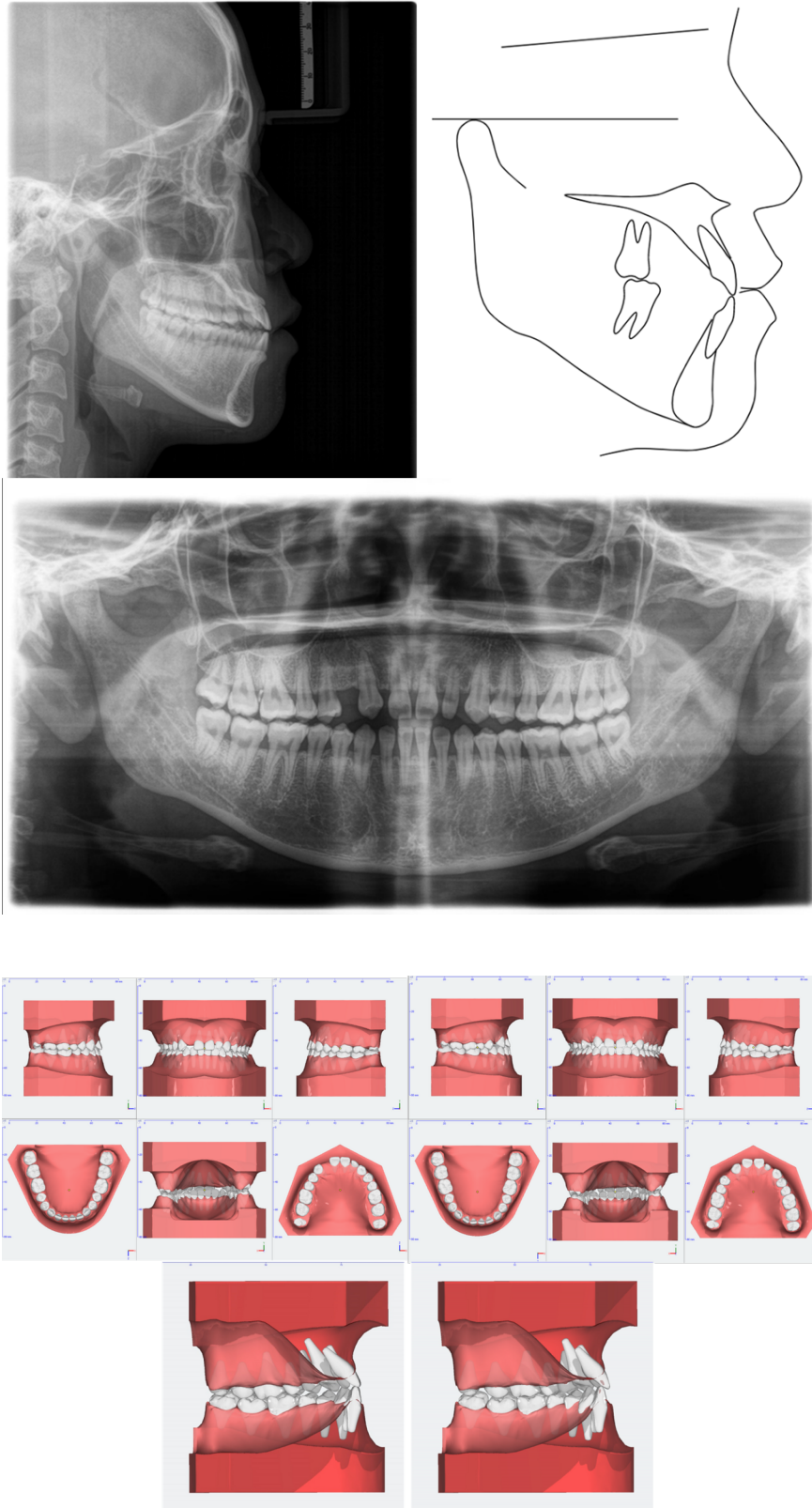


Figure 3: Pre-treatment 3D digital model, 3D simulation before treatment and PIP design

Figure 4: Fixed Orthodontic treatment progress – 6 months

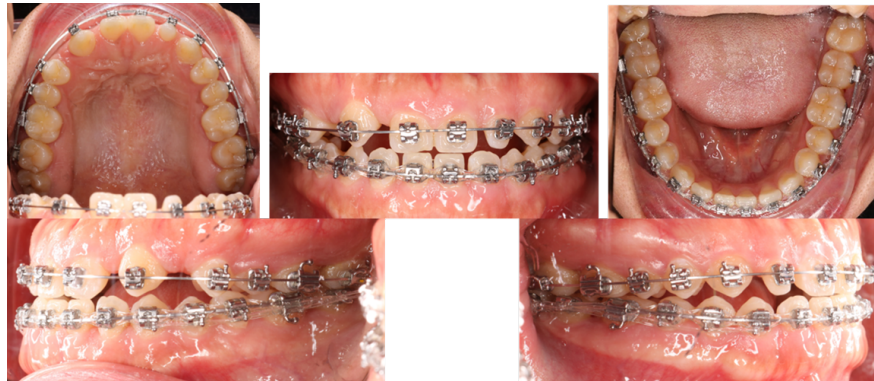

Figure 5: Fixed Orthodontic treatment progress – 8 months

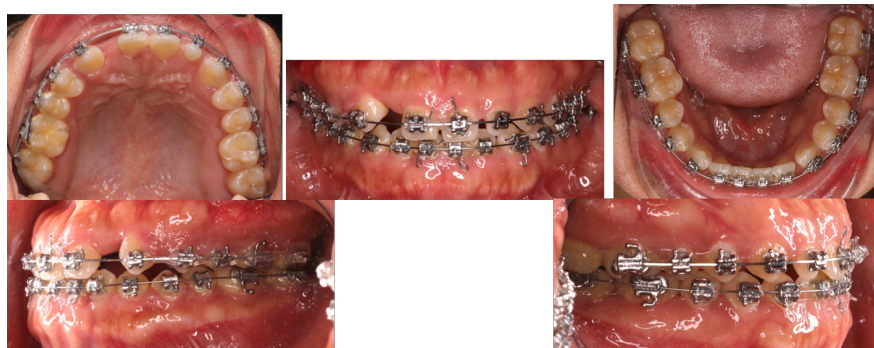

Figure 6: Fixed Orthodontic treatment progress – 11 months – Implant placement

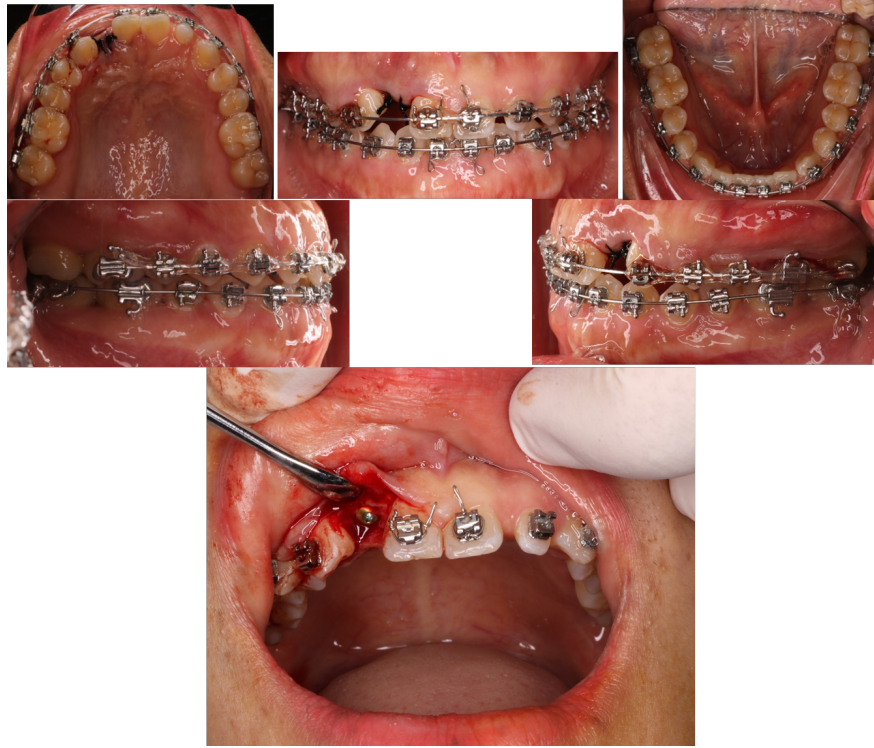


Figure 7: Orthodontic treatment progress – 12 months – temporary crown of 12.

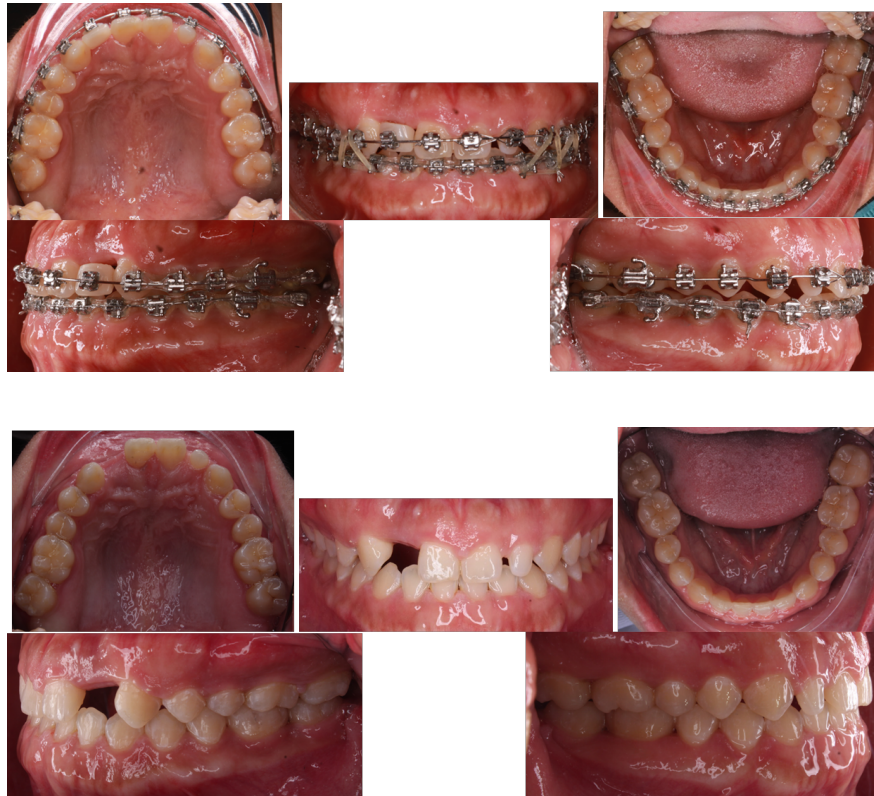


Figure 8: Intra oral pictures after orthodontic treatment – 15 months.

Figure 9: Extra oral pictures after orthodontic treatment – 15 months.



Figure 10: X rays after orthodontic treatment – 15 months.

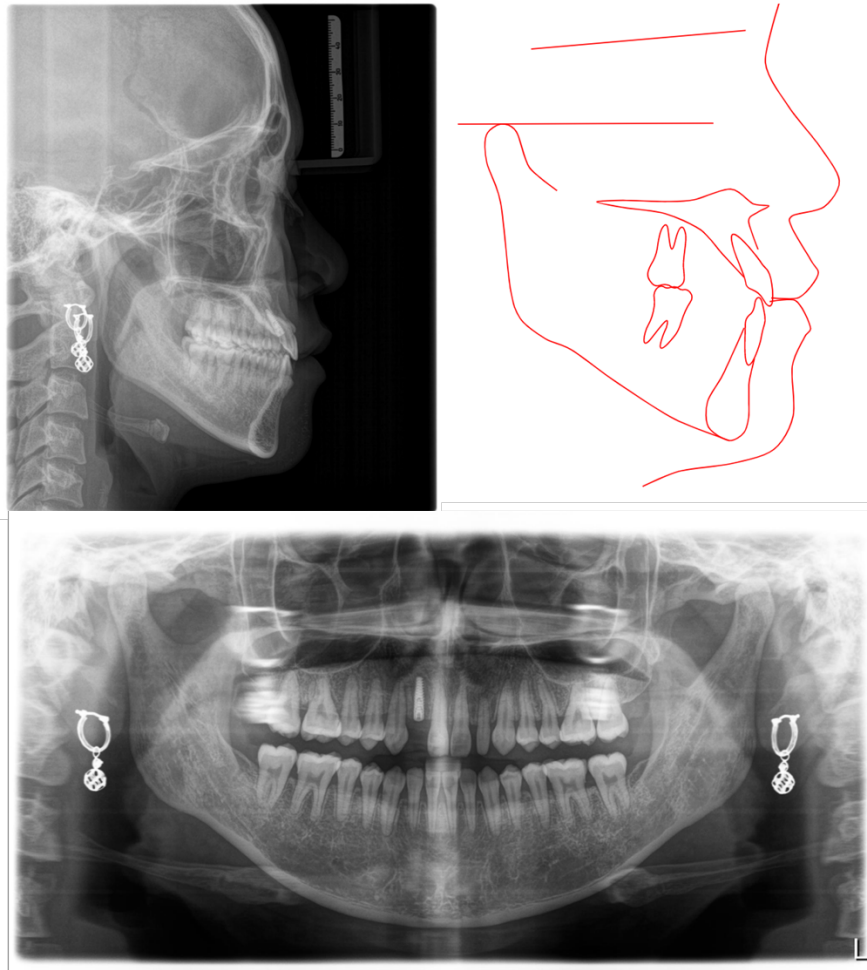


Figure 11: Superimposition pre and post orthodontic treatment.

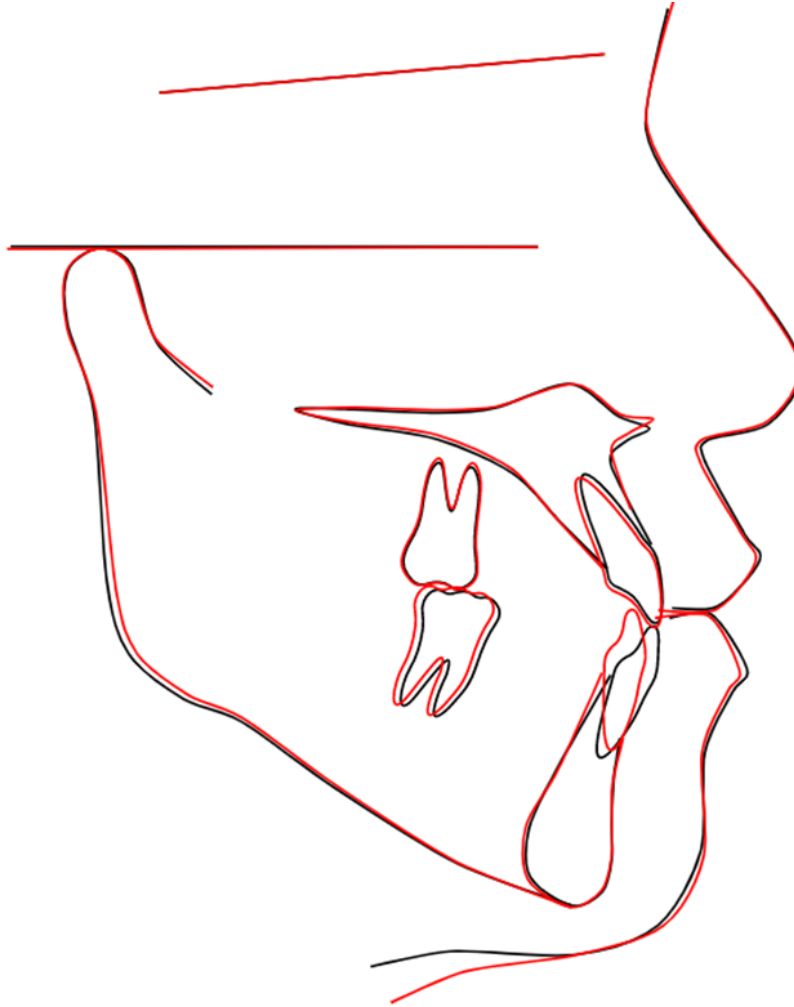


Figure 12: Gingivoplasty surgery after orthodontic treatment completion.

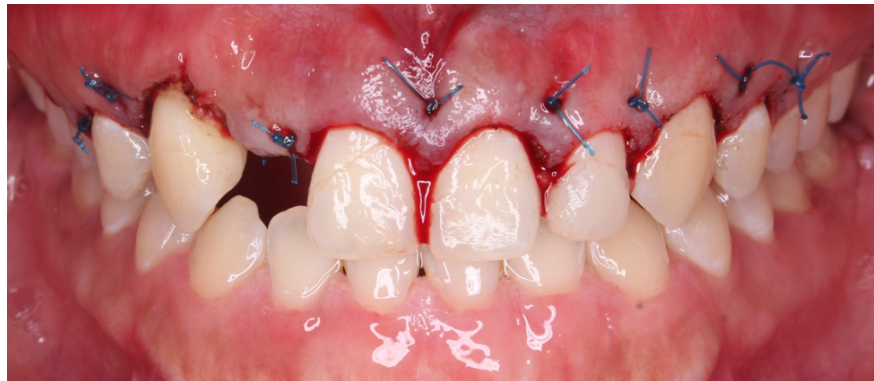

Figure 13: Prosthodontic treatment – Veneer and crown preparation

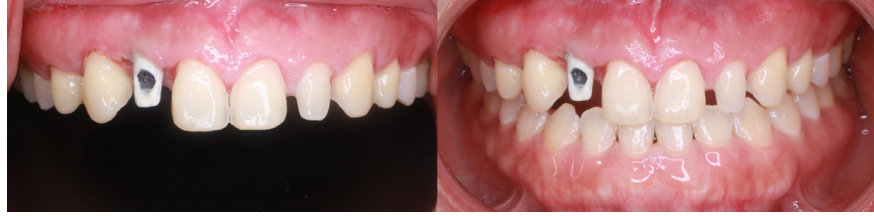

Figure 14: After prosthodontic treatment

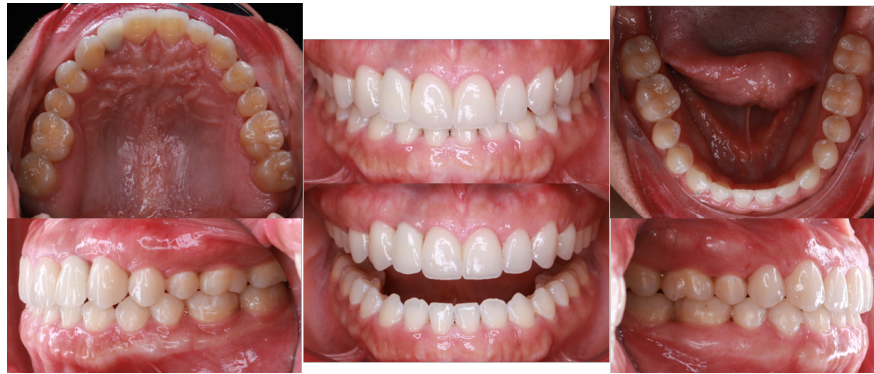
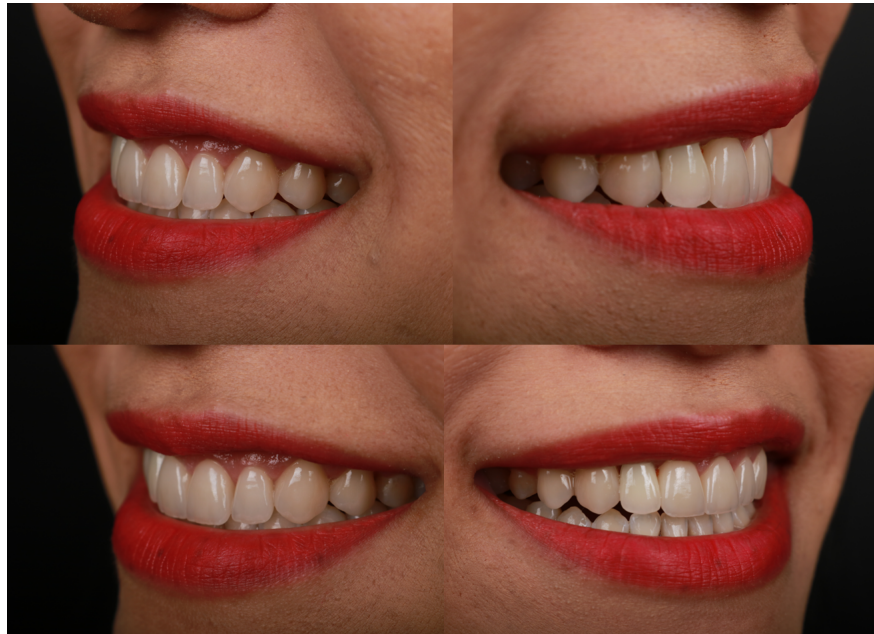
Figure 15: Smile of patient post-treatment



Figure 16: Pre and post treatment extra-oral smile comparison

Figure 17: 6 months follow-up.



Measurement

- SNA (°)
- SNB (°)
- ANB (°)
- FMA (°)
- U1 – SN (°)

Measurement

U1 - NA (mm)

U1-NA (°)

U1 - L1 (°)

L1 - NB (mm)

L1-NB (°)

IMPA (°)

UL - E line (mm)

LL - E line (mm)

ANB: A point, nasion, B point, FMA: Frankfort mandibular plane angle, IMPA: Incisor mandibular plane angle, L1: Lower

Table 1: cephalometric analysis pre and post orthodontic treatment.