

Disseminated Neurocysticercosis with Intraventricular and Cisternal Extension without Hydrocephalus: A Case Report

Bibek Shrestha¹, Priyesh Shrestha², Bikram Gajurel², Grishma Kandel¹, and Laxmi Shah²

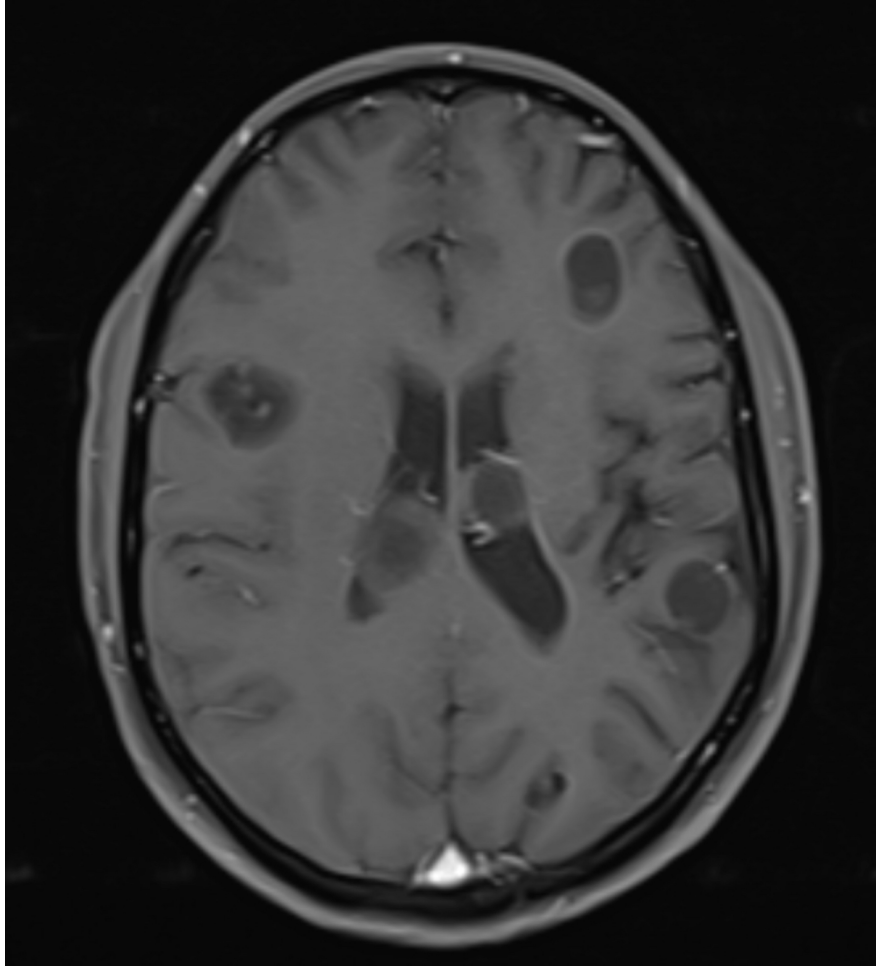
¹Tribhuvan University Institute of Medicine

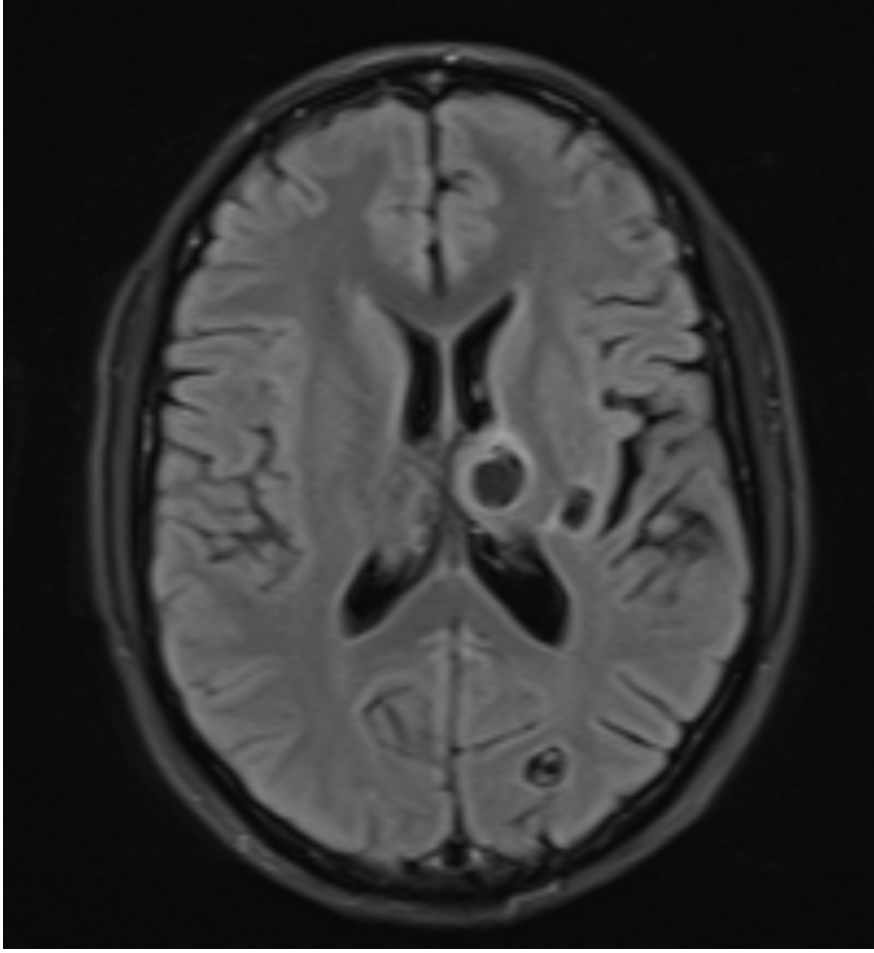
²Tribhuvan University Teaching Hospital

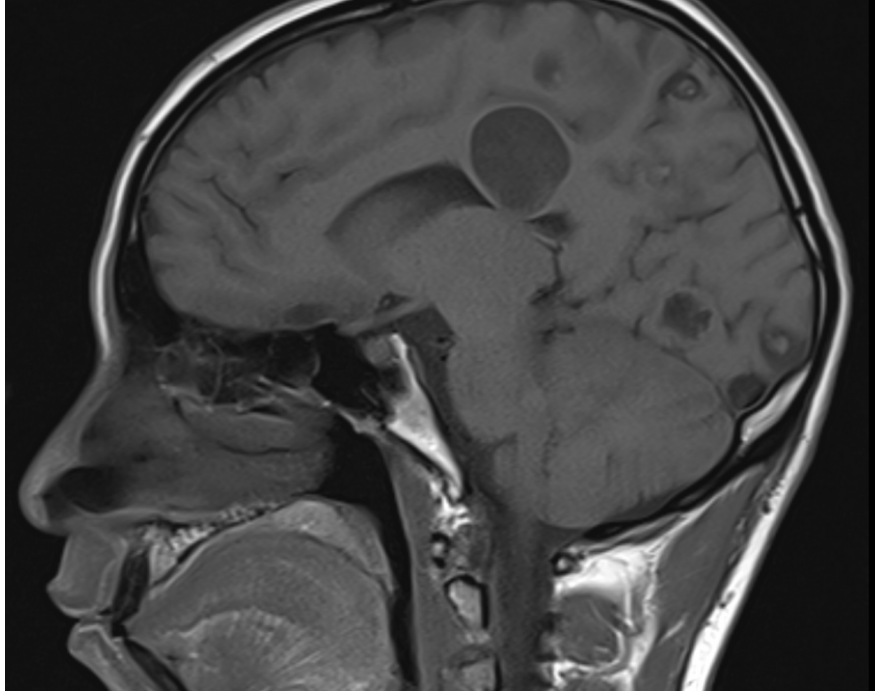
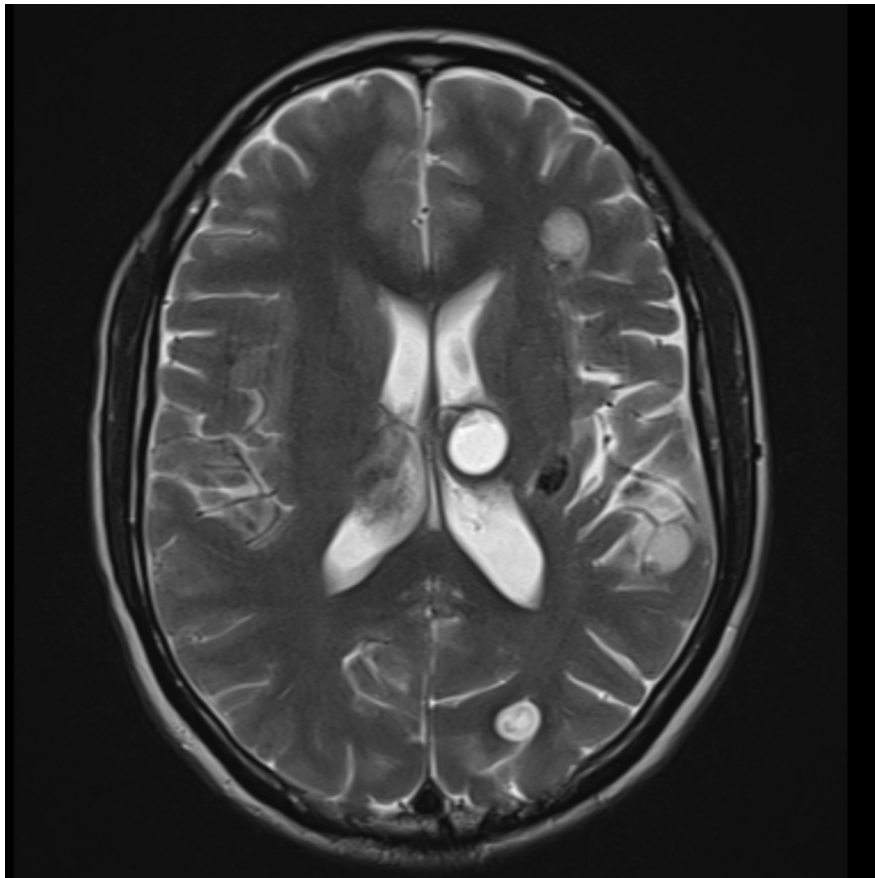
December 18, 2024

Hosted file

Case Report NCC.docx available at <https://authorea.com/users/823487/articles/1252759-disseminated-neurocysticercosis-with-intraventricular-and-cisternal-extension-without-hydrocephalus-a-case-report>







Hosted file

Table 1 Laboratory report.docx available at <https://authorea.com/users/823487/articles/1252759-disseminated-neurocysticercosis-with-intraventricular-and-cisternal-extension-without-hydrocephalus-a-case-report>