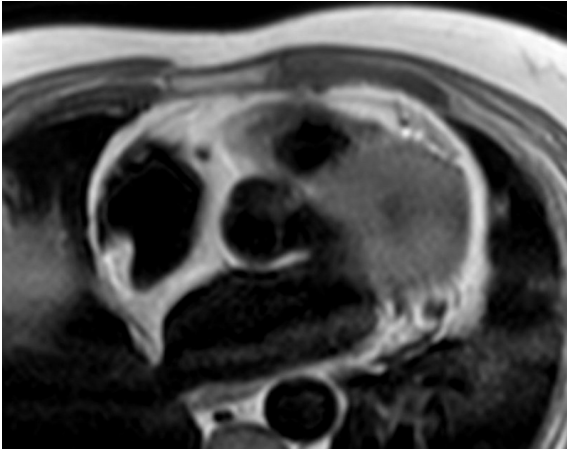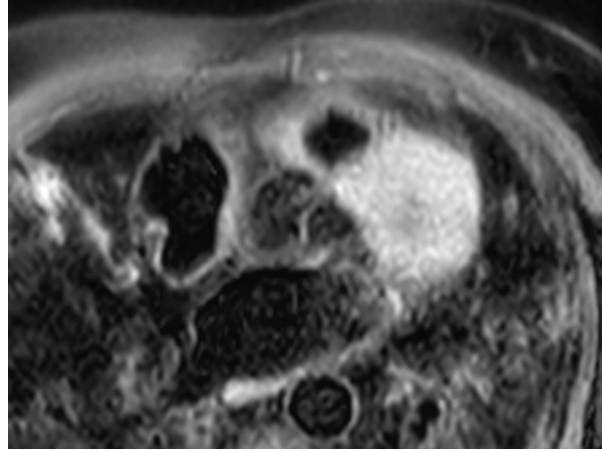


A



B

Figure 3: (A), T1-weighted axial stack illustrates uniform signal of the RA structure and the interatrial septum with a signal intensity identical to the subcutaneous fat. (B), T1-weighted fat saturation images illustrates fat suppression on the RA structure and the interatrial septum.