

Figures:

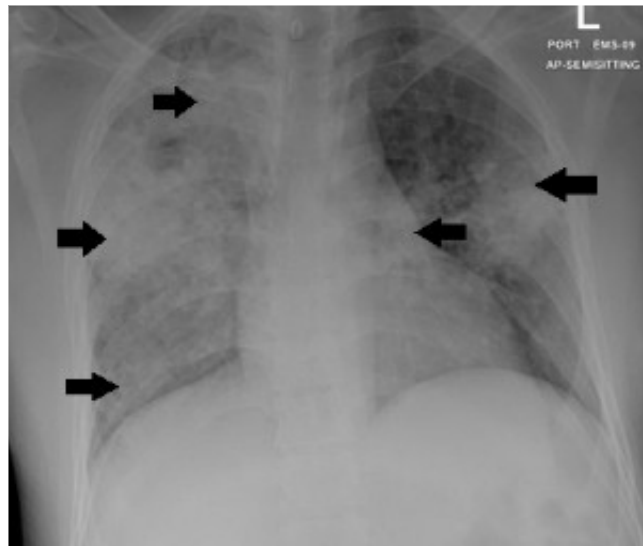


Figure 1: Chest XR: extensive non-homogenous infiltrates in the right lung and left middle zone marked with black arrows.

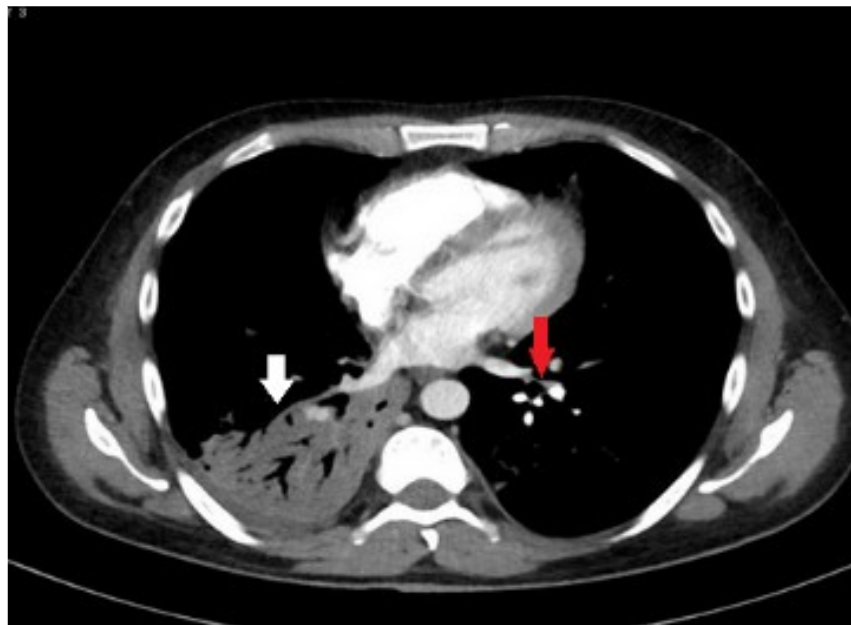


Figure 2: CT pulmonary angiogram (CTPA) remarkable for consolidation marked with white arrow on the right side and area of filling defect in the left pulmonary artery marked with red arrow