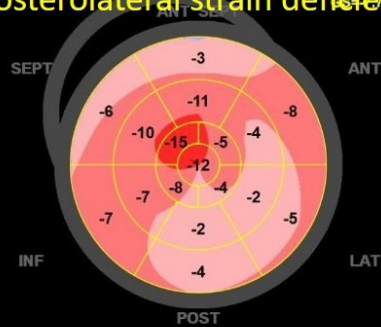


Posterolateral strain deficiency



Increased wall thickness (*)

LV

LA

Phasic LA function

Papillary muscle hypertrophy (*)

LV

