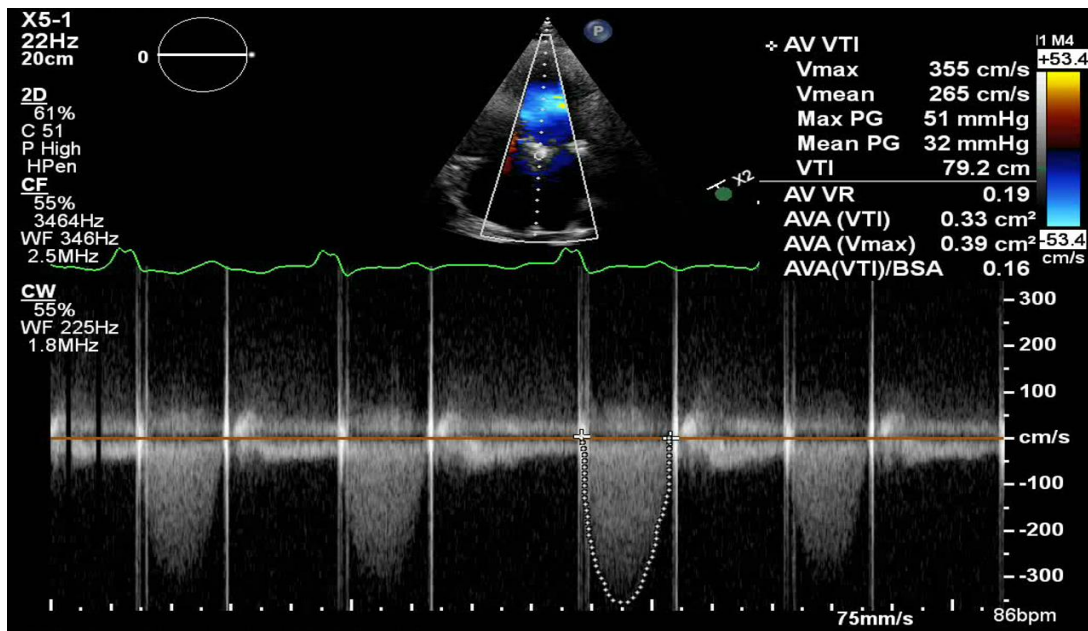


Figure 1 Transprosthetic Pressure Gradient on Transthoracic Echocardiography



Transthoracic echocardiography showing increased Transprosthetic pressure gradient (PG) (maximum PG 51mmHg; mean PG 32mmHg). VTI – Velocity time integral