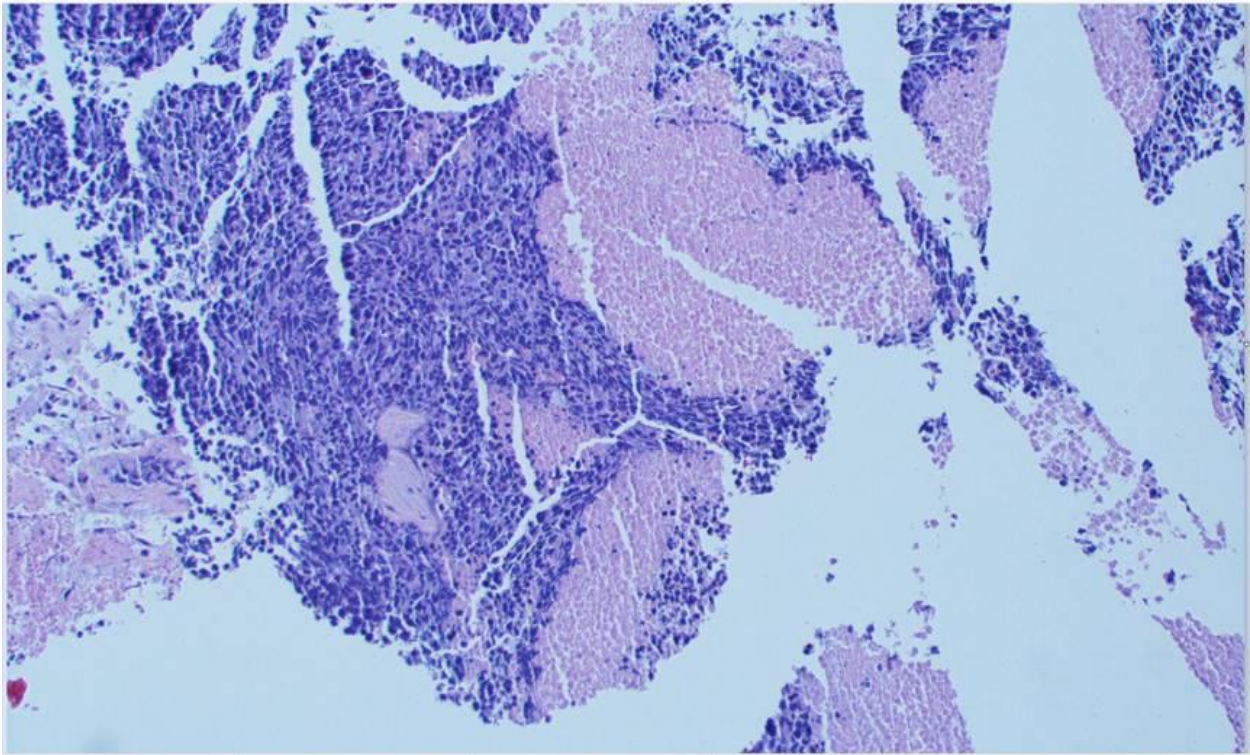


Figure 1. A: Low power magnification (10X) image that shows proliferation of neoplastic cells with extensive geographic necrosis. B: high power magnification (60X) image that shows neoplastic cells with sheets of large atypical cells with irregular nuclear borders, vesicular chromatin and prominent nucleoli. Apoptosis and atypical mitosis are abundant.

A.



B.



Figure 2. 10x magnification of tumor with expression of p16. The darker areas are viable tumor which show cytoplasmic and nuclear expression of p16.

